SEMINARIO

Mapeo vascular facial guiado por ultrasonido: Aprenda los conceptos básicos de la anatomía facial para evitar complicaciones isquémicas

Enero 2023

clarius

Su anfitrión

Rudy Meijer

Especialista Clínico

Europa |Medio Oriente | África

clarius Ultrasound Anywhere

La Seguridad es lo Primero Mejor prévenir que tratar las complicaciones

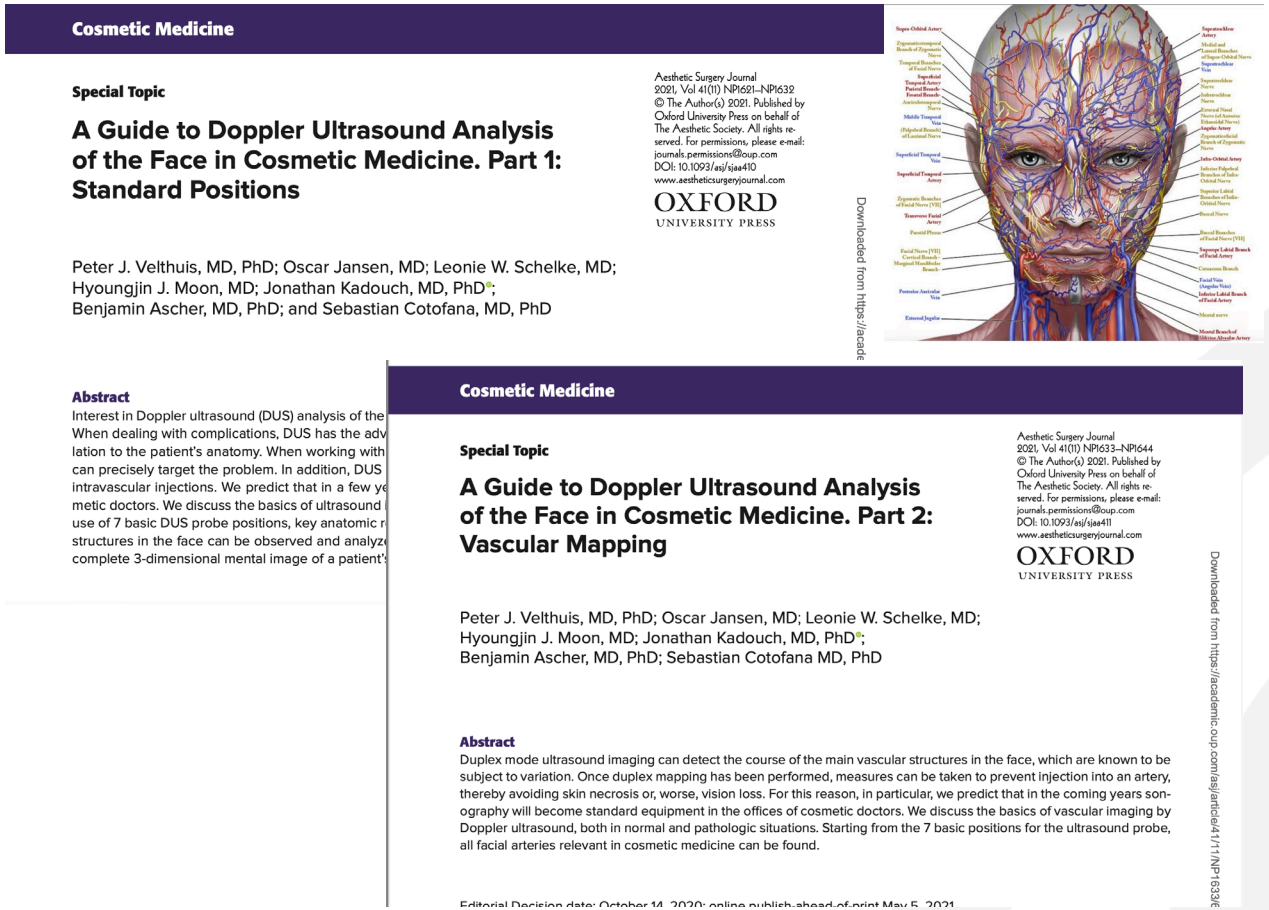

Cosmetic Medicine

Special Topic

A Guide to Doppler Ultrasound Analysis of the Face in Cosmetic Medicine. Part 1: Standard Positions

Aesthetic Surgery Journal
2021, Vol 41(11) NP1621–NP1632
© The Author(s) 2021. Published by Oxford University Press on behalf of The Aesthetic Society. All rights reserved. For permissions, please e-mail: journals.permissions@oup.com
DOI: 10.1093/asj/sjaa410
www.aestheticsurgeryjournal.com
OXFORD UNIVERSITY PRESS

Peter J. Velthuis, MD, PhD; Oscar Jansen, MD; Leonie W. Schelke, MD; Hyoungjin J. Moon, MD; Jonathan Kadouch, MD, PhD; Benjamin Ascher, MD, PhD; and Sebastian Cotofana, MD, PhD

Downloaded from https://acade

Abstract
Interest in Doppler ultrasound (DUS) analysis of the
When dealing with complications, DUS has the adv
lation to the patient's anatomy. When working with
can precisely target the problem. In addition, DUS
intravascular injections. We predict that in a few ye
metic doctors. We discuss the basics of ultrasound
use of 7 basic DUS probe positions, key anatomic r
structures in the face can be observed and analyze
complete 3-dimensional mental image of a patient's

Cosmetic Medicine

Special Topic

A Guide to Doppler Ultrasound Analysis of the Face in Cosmetic Medicine. Part 2: Vascular Mapping

Aesthetic Surgery Journal
2021, Vol 41(11) NP1633–NP1644
© The Author(s) 2021. Published by Oxford University Press on behalf of The Aesthetic Society. All rights reserved. For permissions, please e-mail: journals.permissions@oup.com
DOI: 10.1093/asj/sjaa411
www.aestheticsurgeryjournal.com
OXFORD UNIVERSITY PRESS

Peter J. Velthuis, MD, PhD; Oscar Jansen, MD; Leonie W. Schelke, MD; Hyoungjin J. Moon, MD; Jonathan Kadouch, MD, PhD; Benjamin Ascher, MD, PhD; Sebastian Cotofana MD, PhD

Abstract
Duplex mode ultrasound imaging can detect the course of the main vascular structures in the face, which are known to be subject to variation. Once duplex mapping has been performed, measures can be taken to prevent injection into an artery, thereby avoiding skin necrosis or, worse, vision loss. For this reason, in particular, we predict that in the coming years sonography will become standard equipment in the offices of cosmetic doctors. We discuss the basics of vascular imaging by Doppler ultrasound, both in normal and pathologic situations. Starting from the 7 basic positions for the ultrasound probe, all facial arteries relevant in cosmetic medicine can be found.

Editorial Decision date: October 14, 2020; online publish-ahead-of-print May 5, 2021

Downloaded from https://academic.oup.com/asj/article/41/11/NP1633/6

- *El conocimiento en tiempo real de la anatomía vascular y la correcta aplicación de la ecografía son claves*
- *El mapeo ayudará a evitar las inyecciones intravasculares de rellenos dérmicos (zona de peligro)*
- *Observe el cambio de capa inesperado y la variación de la anatomía vascular antes del procedimiento*
- *Aumentar la confianza y la satisfacción del paciente*

Qué necesitas en un escáner para Estética Facial

- *Escáner de matriz lineal (2-5 cm) de alta frecuencia/resolución (15-20 MHz)*
- *Excelente sensibilidad Doppler color/power para visualizar la microvascularización*
- *Extrema facilidad de uso y herramientas/tecnologías intelig entes para obtener información esencial (AI)*
- *Desinfección sencilla*

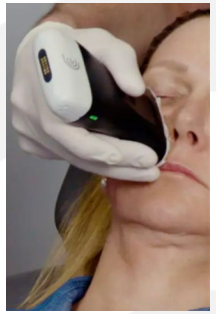

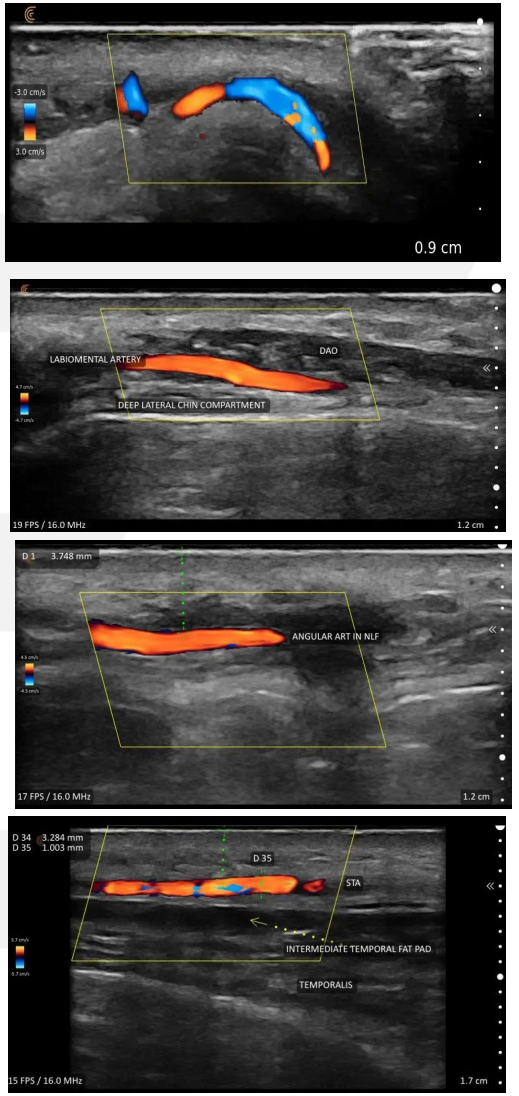

clarius Ultrasound Anywhere

Encuesta

¿Cree que el uso de la ecografía en la Estética facial será obligatorio en el futuro?

- *Si*
- *No*
- *No sé*

Su orador invitado experto

Dra. Karina Ravera, MD

Médica Especialista en Diagnóstico por Imágenes

Post grado en Medicina Estética

clarius Ultrasound Anywhere

clarius

AMWC LATIN AMERICA

Mapeo vascular facial guiado por ultrasonido:

Aprenda los conceptos básicos de la anatomía facial para evitar complicaciones isquémicas

Dra. Karina Ravera
Médica Especialista en Diagnóstico por Imágenes
Post grado en Medicina Estética
Argentina

Dra. Karina Ravera

- Médica Especialista Diagnóstico por Imágenes
- Posgrado en Medicina Estética Universidad de Buenos Aires
- Miembro Patient Safety Committee Craniofacial Research and Study Center Miami University USA
- Directora Medica de Ultraskinus , plataforma de aprendizaje de Ecografía Cutánea e Intervencionismo Percutáneo
- Scientific advisor Dermica Laboratoires
- Docente Master Medicina Estética Universidad Católica de Valencia
- Miembro European Medical College

UltraSkinUS

ULTRASOUND BASIC & ADVANCED TRAINING

Índice

1 - Importancia de la visualización y localización de las estructuras vasculares

2 - Mapeo vascular

3 - Inyecciones ecoguiadas para evitar accidentes vasculares

-Surco Nasogeniano
-Labios
-Pómulos
-Fosa temporal

PubMed.gov

Aesthet Surg J. 2022 Sep 14;42(10):1145-1151. doi: 10.1093/asj/sjac060.

Upper Facial Anastomoses Between the External and Internal Carotid Vascular Territories – A 3D Computed Tomographic Investigation

Zhen-Hao Li [1], Michael Alfertshofer [2], Wei-Jin Hong [1], Xin-Rui Li [1], You-Liang Zhang [1], Nicholas Moellhoff [2], Konstantin Frank, Sheng-Kang Luo [1], Sebastian Cotofana [3]

IRRIGACIÓN SANGUÍNEA FACIAL

ACE

1. A. Facial
2. A. Temporal Superficial
3. A. Maxilar (A. Infraorbitaria)

ACI

1. A. Supraorbitaria
2. A. Supratroclear
3. A. Dorsal Nasal

" Efecto antifaz "

(ramas de A. Oftámica)

Plastic Surgery Key
Fastest Plastic Surgery & Dermatology Insight Engine

Arteries of the Face and Neck

Yelda Atamaz Pinar, Figen Govsa, and Servet Celik

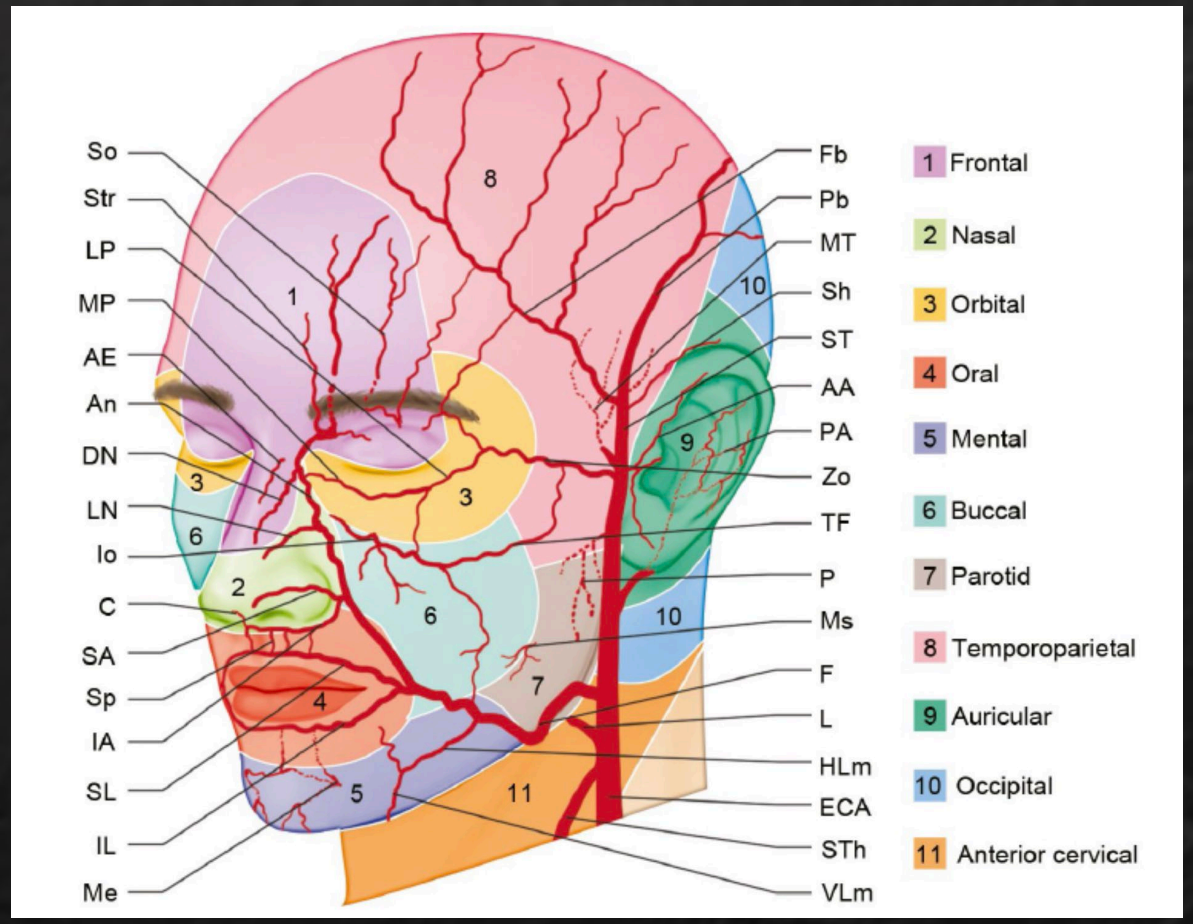

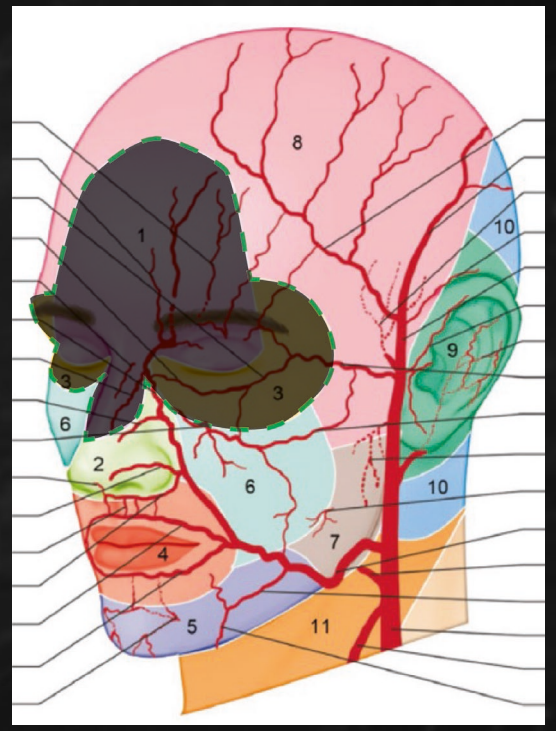

Background: Facial regions with a high risk for causing injection-related visual comprise are dual-supply vascular areas such as the nose, glabella, and forehead. These regions have in common that they receive arterial blood supply both by branches of the internal (ICA) and the external carotid artery (ECA).

clarius

Irrigación arterial de la cara

Anastomosis Intercarotídeas ACI-ACE

1 a 5 conexiones anastomóticas
Planos superficial y profundo

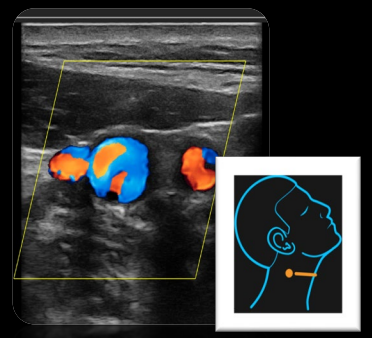

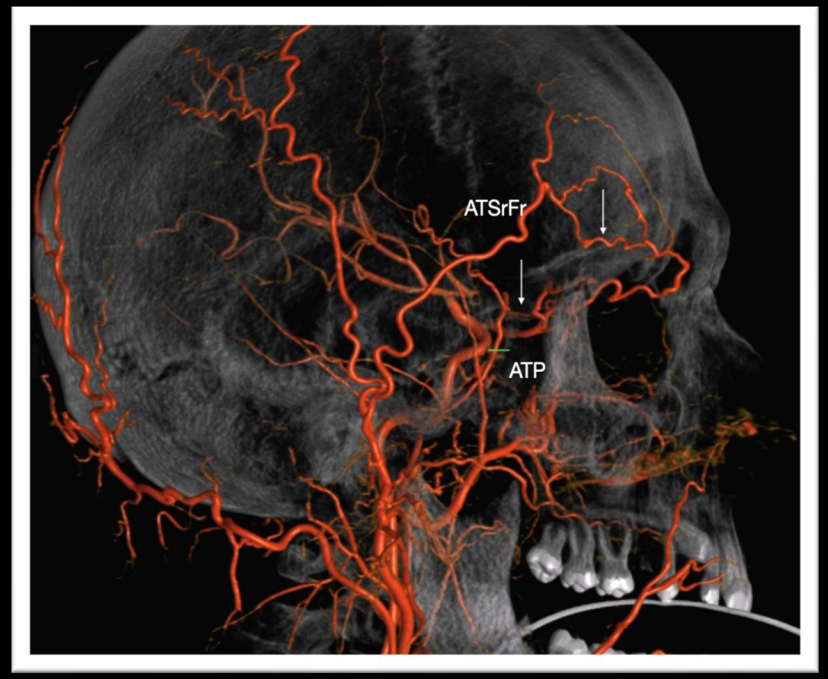

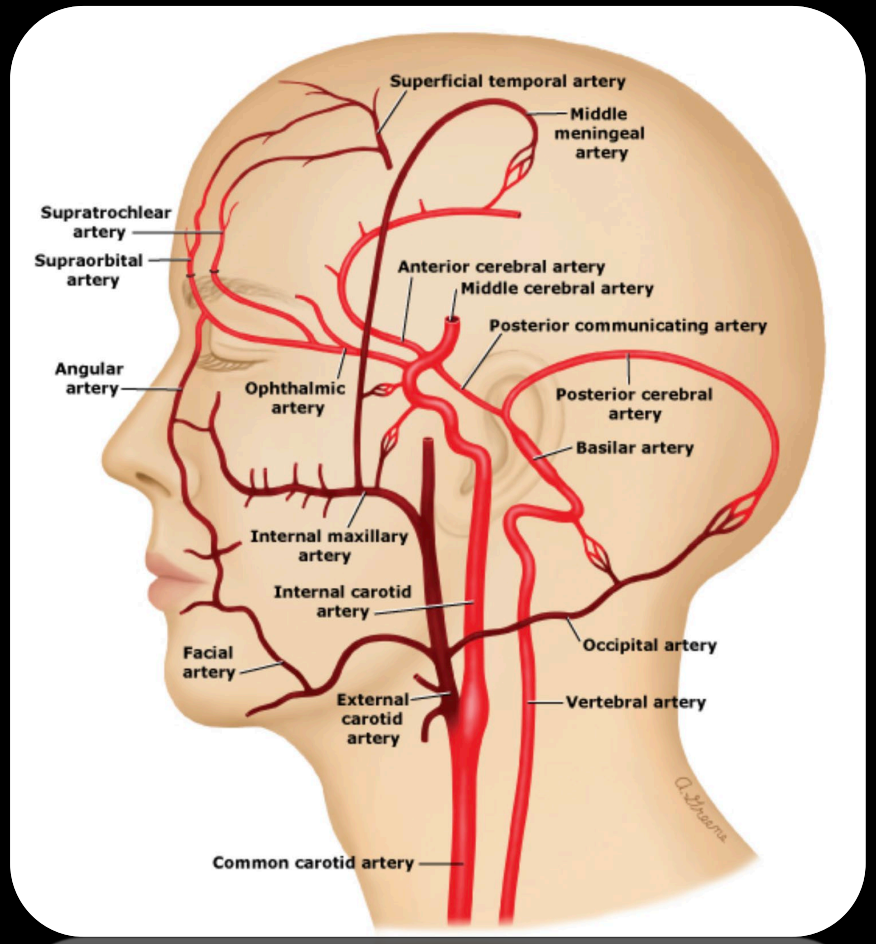

Accidentes vasculares

1 - **Inyección intravascular (A-V)**

2 - **Obstrucciones compresiva externa (A-V)**

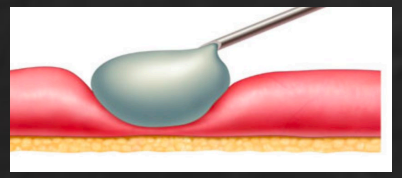

3 - **Espasmo**

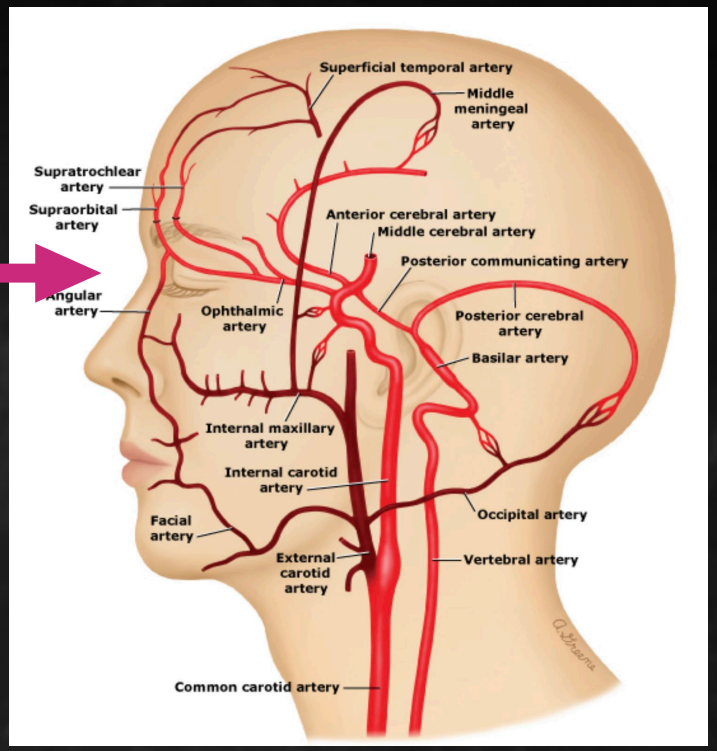

Consecuencias de los eventos vasculares:

- Isquemia tisular diferentes grados
- Ceguera
- Stroke , otros

Plastic Surgery Key
Fastest Plastic Surgery & Dermatology Insight Engine

Vascular Anatomy of the Skin and Muscles

Diego Marré, Michael Tecce, Alejandro Conejero

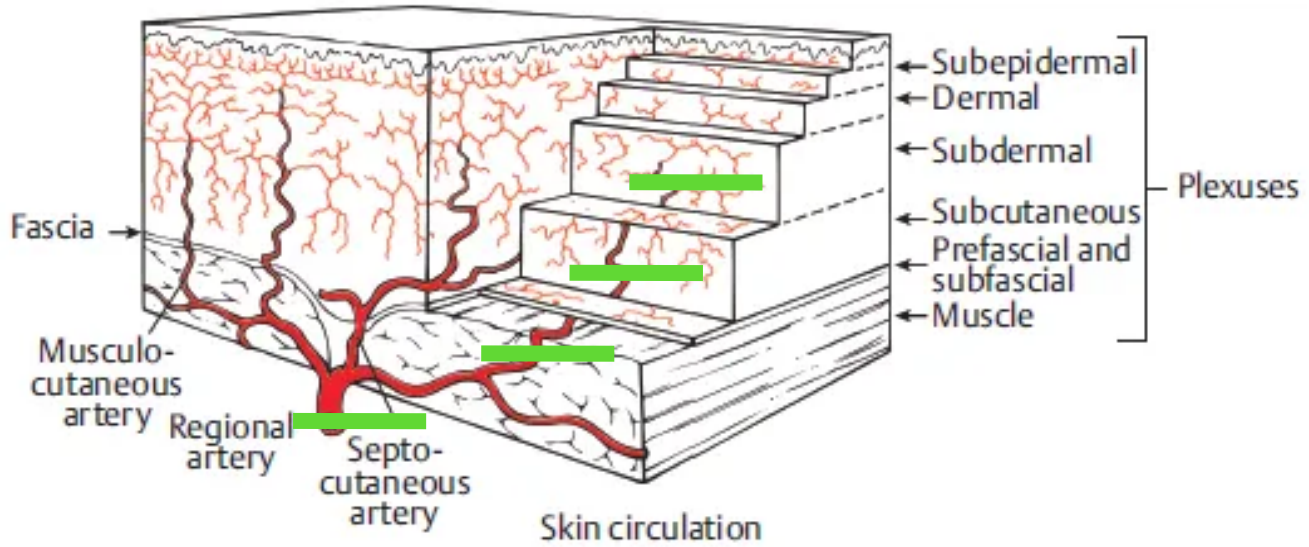

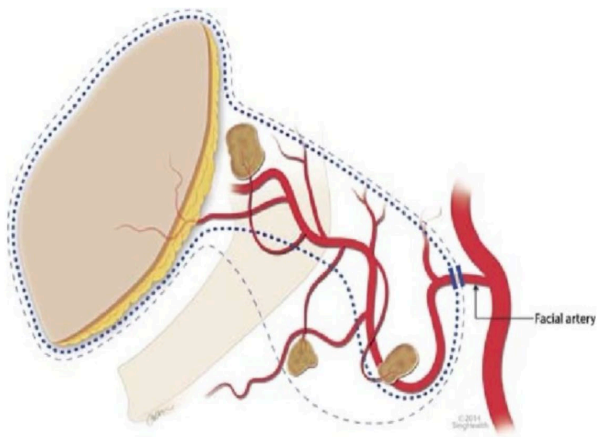

Figure

Caption

FIGURE 5. Perforator to overlying skin paddle separate from the branches supplying the lymph nodes. When dissection carried out from skin to pedicle, if dissection proceeded too close to the pedicle, that is, along dotted pathway, this will result in cutting through hilar blood supply. After visualizing hilar vess els,safe dissection can be ... Read more

This figure was uploaded by Terence Goh
Content may be subject to copyright.

Mapeo vascular

Trayectoria del vaso

Profundidad

Vessel Depth AI

Allow Vessel Depth AI to automatically measure the shallowest flow found in real-time.

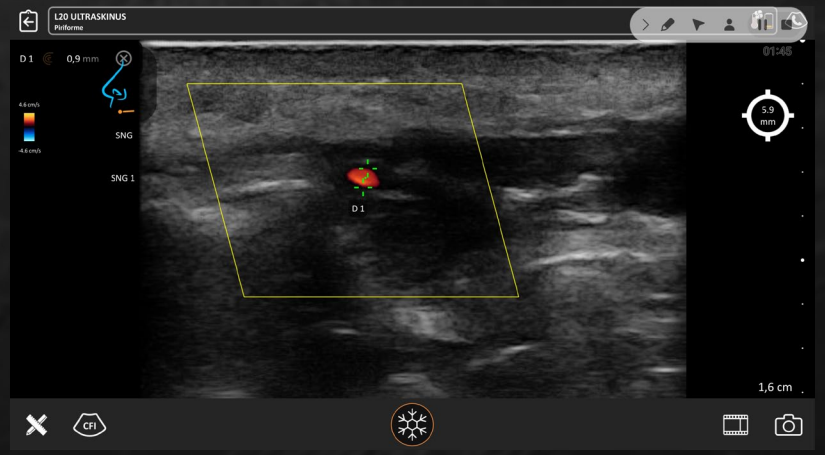

La anatomía es única en cada paciente

Técnica ideal:

Mapeo vascular con US Doppler

Procedimiento ecoguiado

Surco Nasogeniano

Arteria Angular

La arteria Facial-Angular puede tener diversos patrones anatómicos
Y por ende terminar en diferentes puntos de la cara (desde el labio inferior hasta en la frente)

Anatomía Surco Nasogeniano



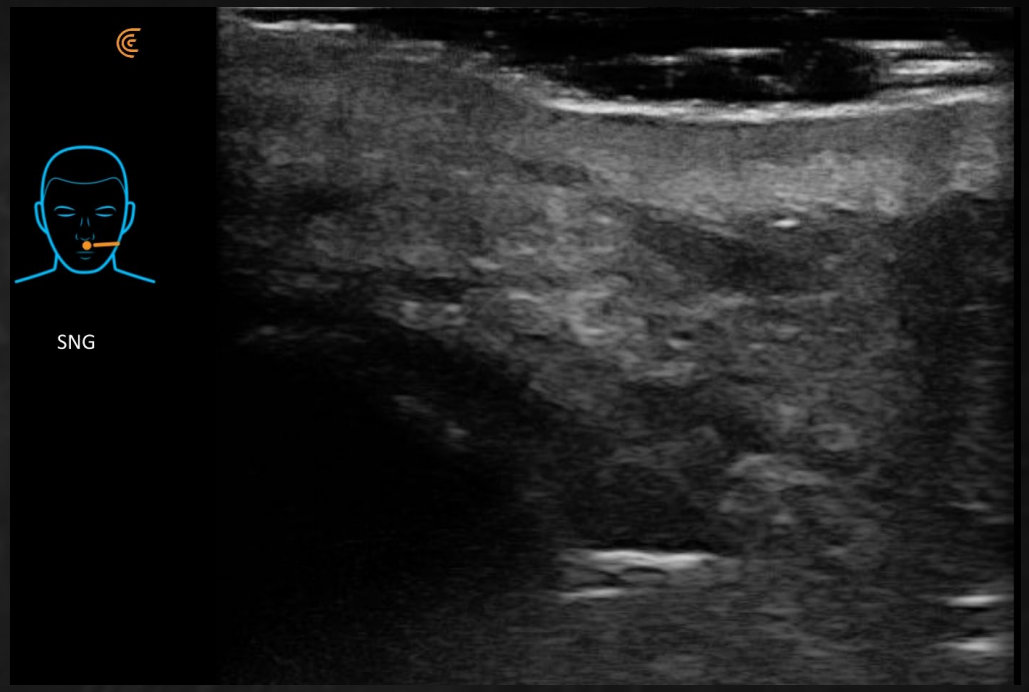

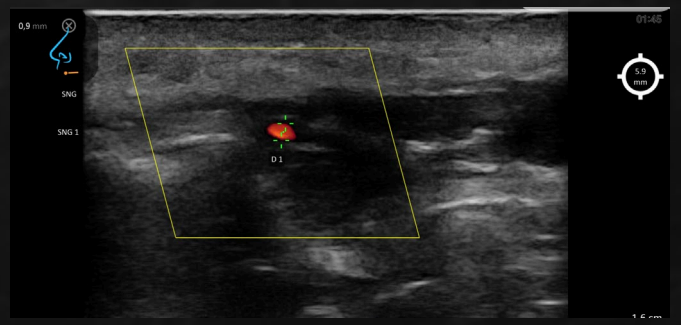

PubMed.gov

A Rare Case of Facial Artery Branching-A Review of the Literature and a Case Report with Clinical Implications

Martin Siwetz [1], Nicol Turnowsky [1], Niels Hammer [1 2 3], Michael Pretterklieber [1], Andreas Wree [4], Veronica Antipova [1 4]

(Estudios anatómicos en cadáveres y radiología)

Posición lateral de la arteria Facial angular en el SNG

“Lateralización”

Número de arterias : 300 surcos NG:
90% 1 arteria
9% 2
1% 0

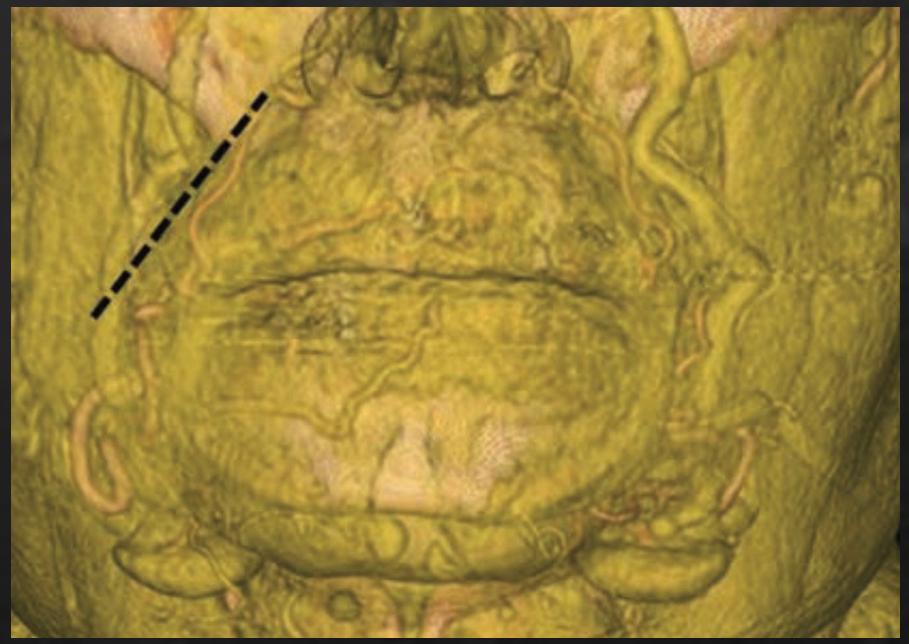

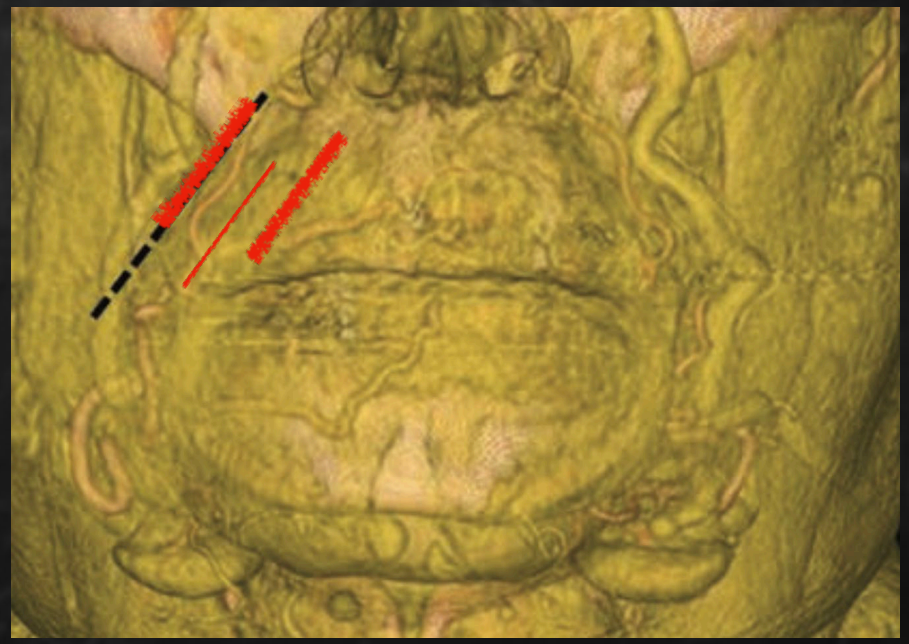

Referencia: Anatomical Map of the Facial Artery for Facial Reconstruction and Aesthetic Procedures Mateusz Koziej, MD, PhD ; Marek Trybus, MD, PhD; Mateusz Hołda, MD, PhD; Jakub Polak; Jakub Wnuk; Paweł Brzegowy, MD, PhD; Tadeusz Popiela, MD, PhD; Jerzy Walocha, MD, PhD; and Anna Chrapusta, MD, PhD

A medida que envejecemos se hace mas superficial y menos lateral debido a la atrofia grasa subcutánea
Es mas superficial en mujeres
Las arterias pueden ser mas numerosas en mujeres

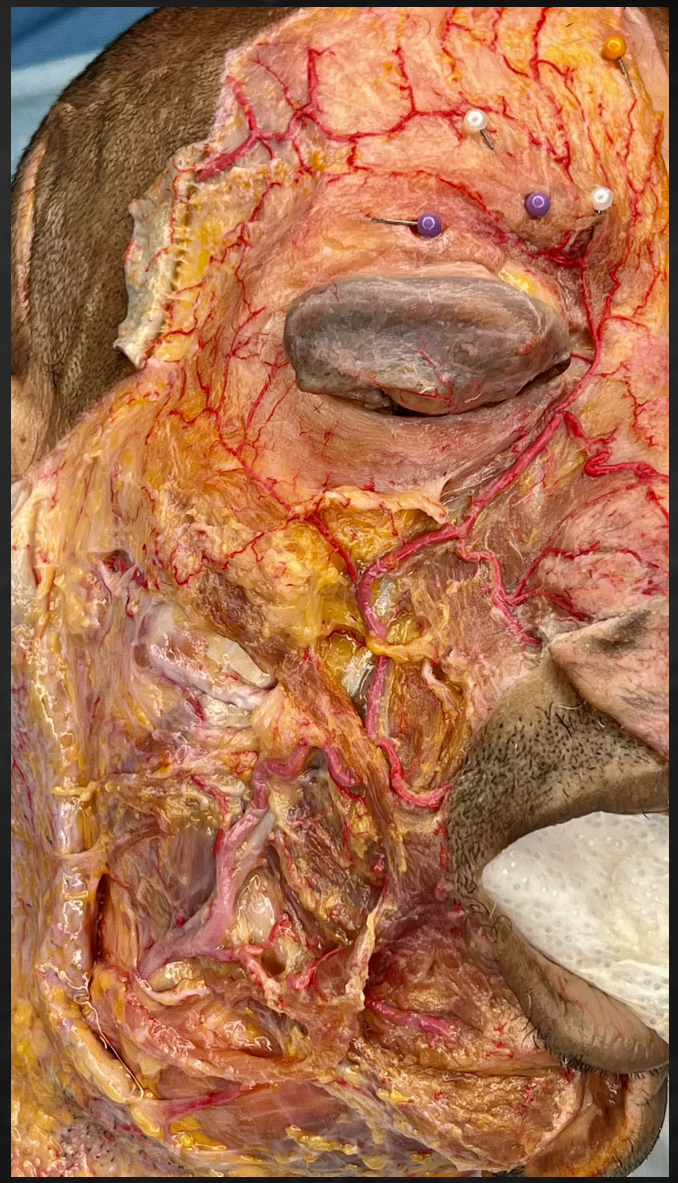

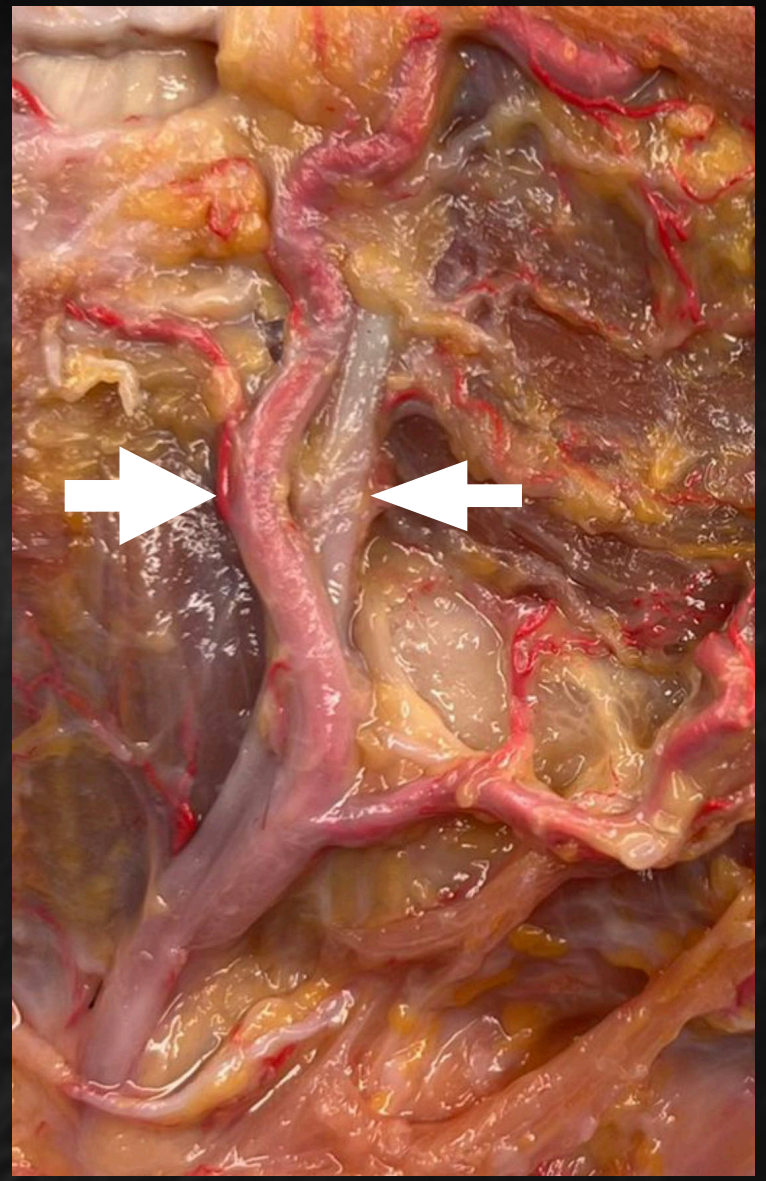

CRANIOFACIAL RESEARCH AND STUDY CENTER

MIAMI FLORIDA

Dr Patricia Oyole
Cirujana Maxilofacial

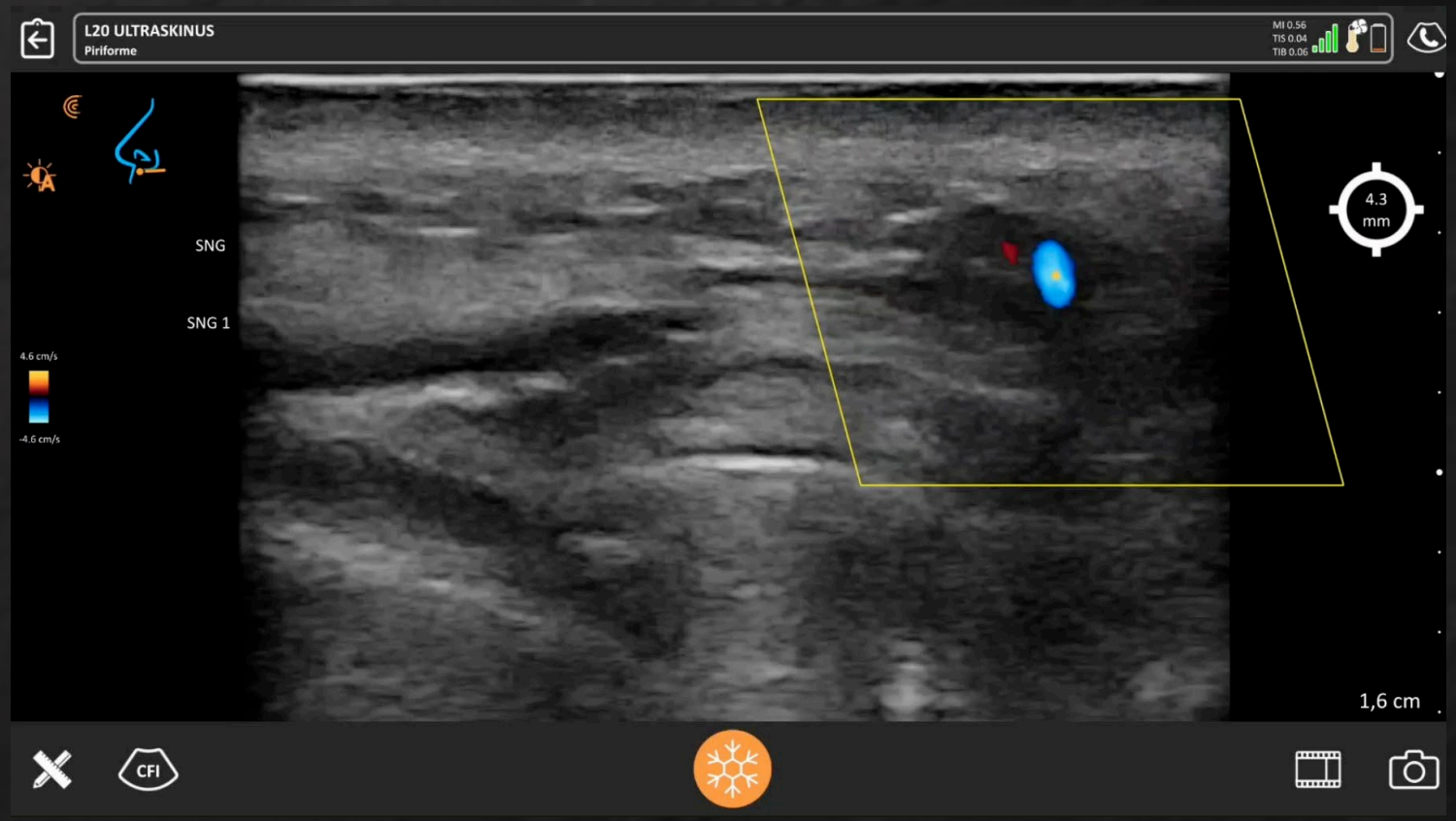
L20 ULTRASKINUS
Piriforme
MI 0.56
TIS 0.04
TIB 0.06
SNG
SNG 1
4.6 cm/s
-4.6 cm/s
4.3
mm
1,6 cm
CFI

SNG
SNG 1
D 1
5.9
mm

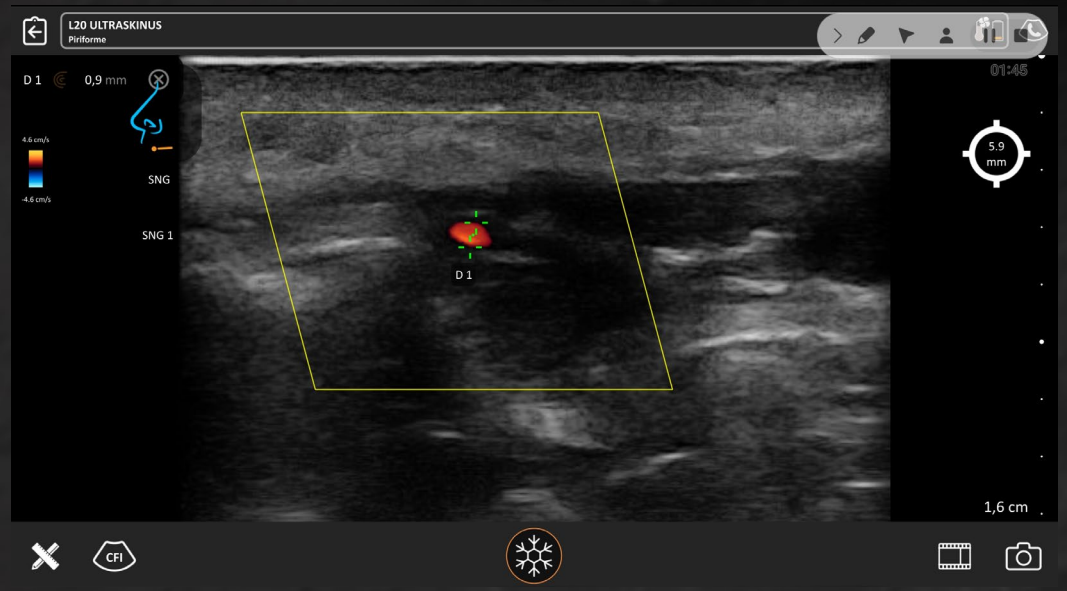
L20 ULTRASKINUS
Piriforme
D 1
0,9 mm
01:45
4.6 cm/s
-4.6 cm/s
SNG
SNG 1
D 1
5.9
mm
1,6 cm
CFI

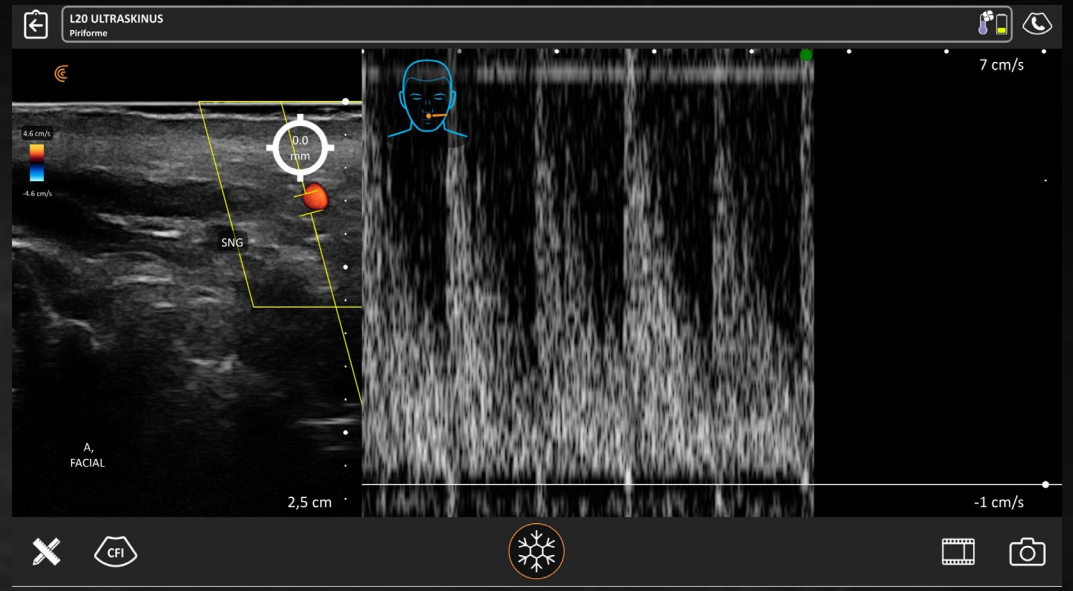
L20 ULTRASKINUS
Piriforme
7 cm/s
4.6 cm/s
-4.6 cm/s
0.0
mm
SNG
A,
FACIAL
2,5 cm
-1 cm/s
CFI

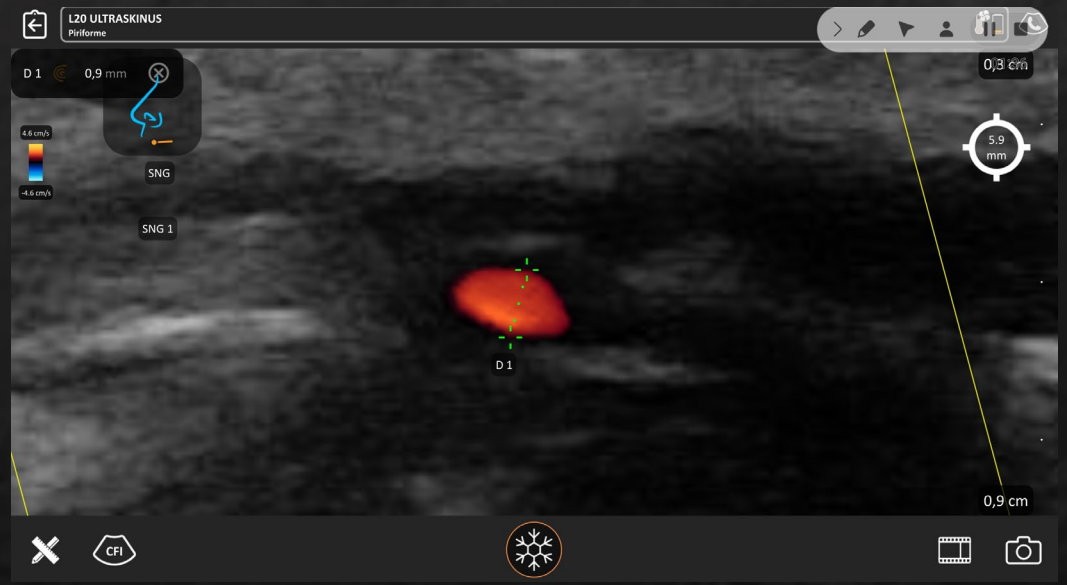
L20 ULTRASKINUS
Piriforme
D 1
0,9 mm
0,3 cm
4.6 cm/s
-4.6 cm/s
SNG
SNG 1
5.9
mm
D 1
0,9 cm
CFI

VIDEO SURCO NASOGENIANO ECO DOPPLER

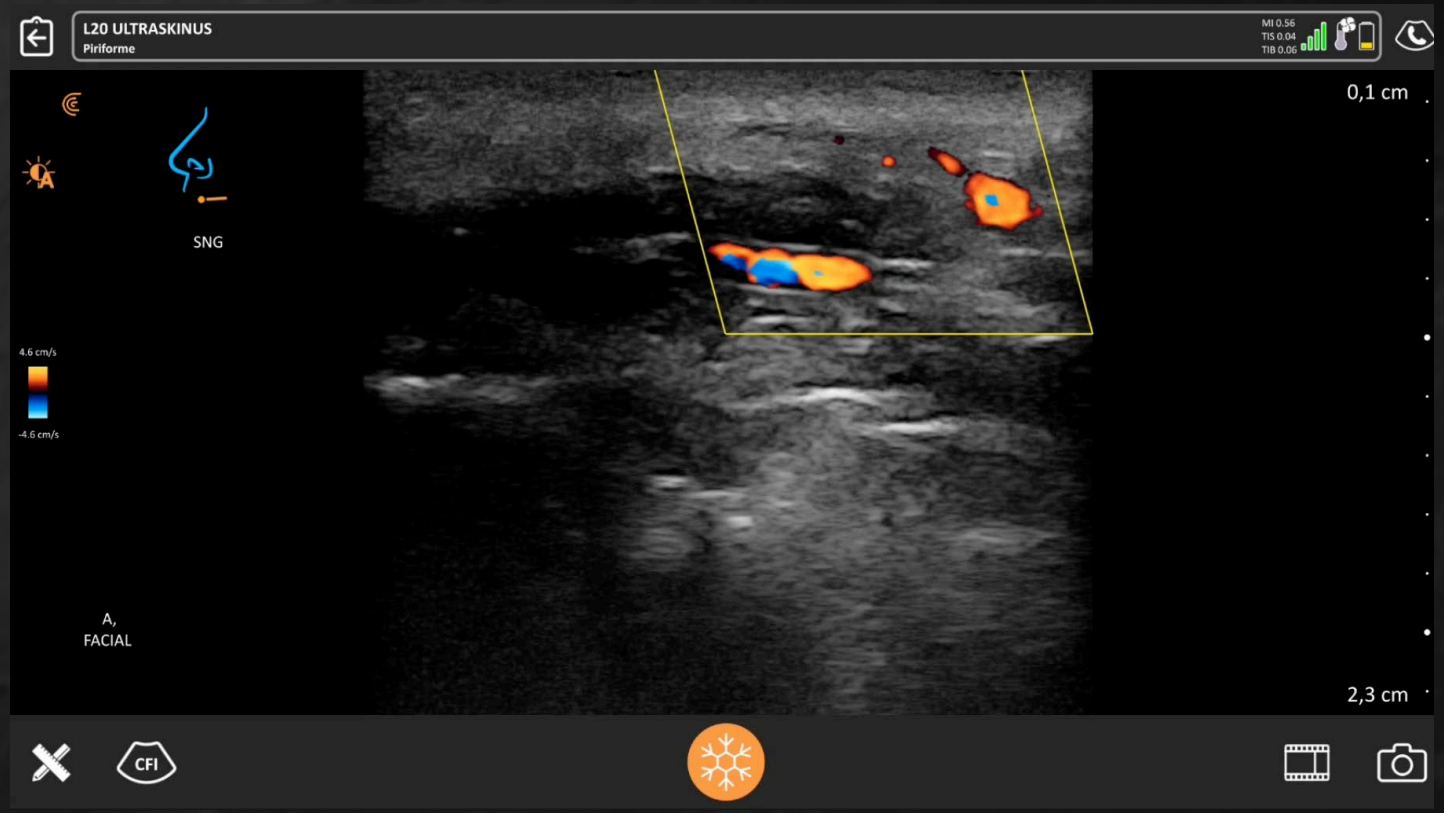

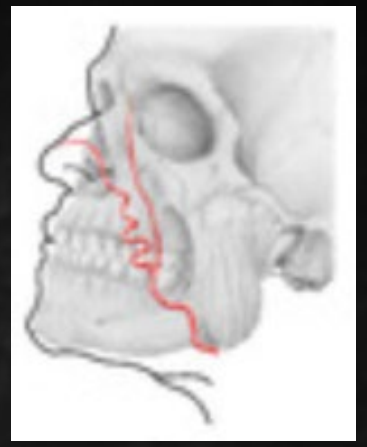

Eleni's L20
Aesthetics
MI 0.56
TIS 0.04
TIB 0.06
3.3 cm/s
-3.3 cm/s
14 FPS / 16.0 MHz
1.9 cm
CFI

CRANIOFACIAL RESEARCH AND STUDY CENTER

MIAMI FLORIDA

Dr Patricia Oyole
Cirujana Maxilofacial

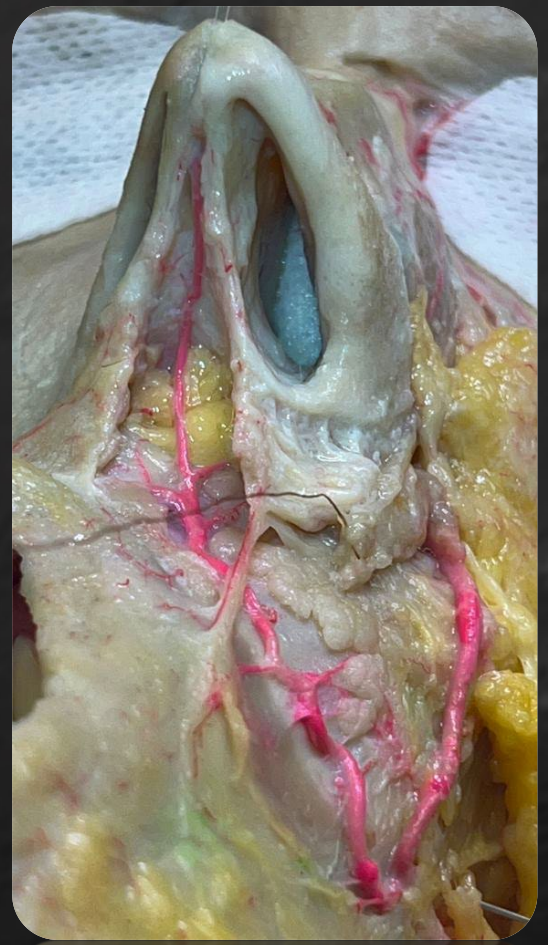

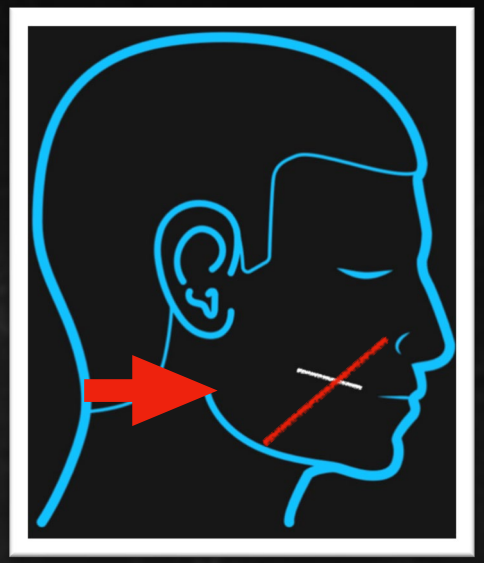

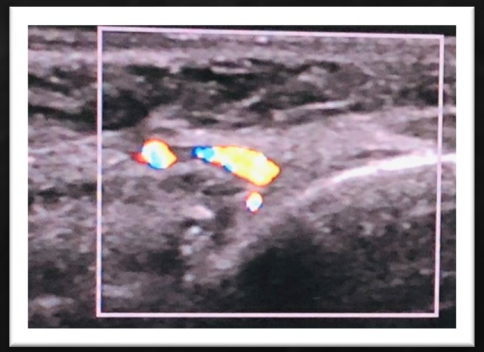

Labios

Estructuras de riesgo vascular :
Arterias labiales superior e inferior

Anastomosis (circulación colateral)
Sin anastomosis

Irrigación de las arterias labiales : labios, nariz, músculos orales

A Labial Superior:
Ramas: A Columelares y A Septal (art septales pueden irrigar ala nasal)a veces las alares provienen de la facial

anastomosis Plexo Kiesselbalch y arteria contralateral

A Labial inferior:
Anatomosis: art labial contralateral y mentonianas

Labio leporino: faltan anastomosis frecuentemente (P Kiesselbach y L contralateral)
Pacientes con labio leporino pueden no tener ninguna circulación colateral !!!!

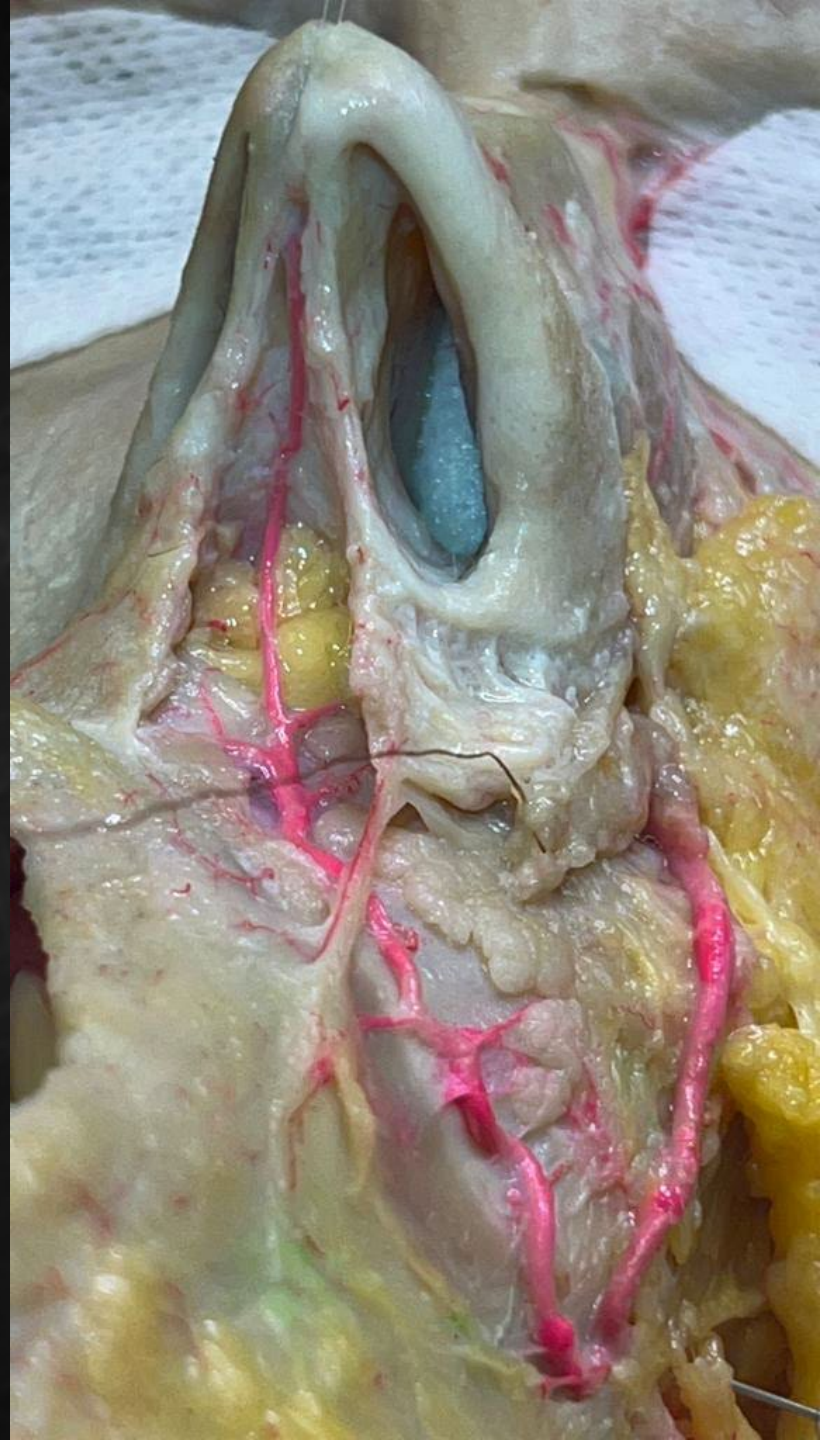

CRANIOFACIAL RESEARCH AND STUDY CENTER
MIAMI FLORIDA
Dr Patricia Oyole
Cirujana Maxilofacial

PubMed.gov

Anatomical Variations in the Course of Labial Arteries: A Literature Review

Souphiyeh Samizadeh [1], Ali Pirayesh, Dario Bertossi [2]

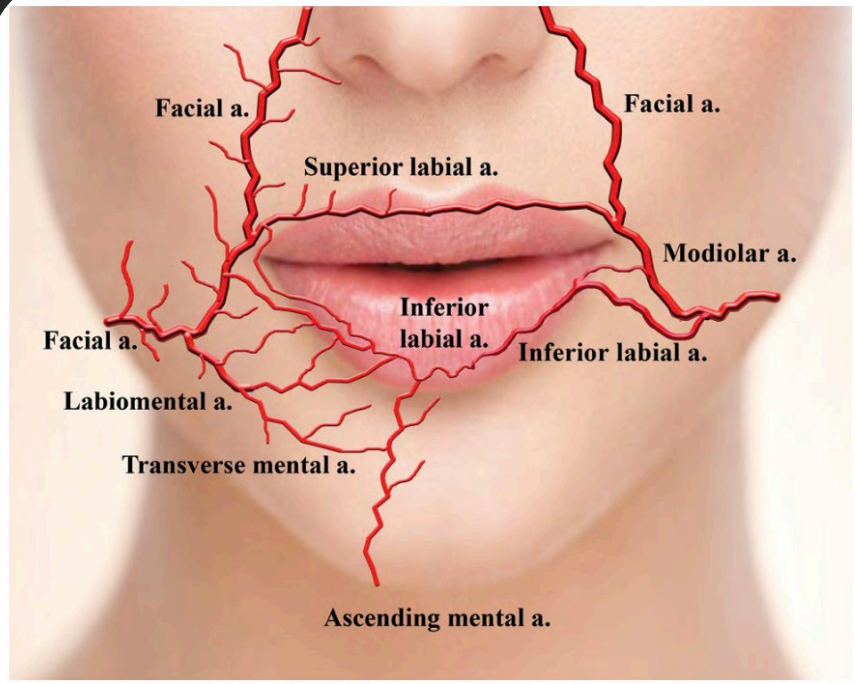

Fig. 1. Five arterial sources of the inferior labial artery and their various combinations.

Arterial Sources of the Inferior Labial Artery
Labiomental artery
Facial artery
Superior labial artery
Ascending mental artery

Posibilidad de
Complicaciones vasculares de variados espectros y
En casos raros ceguera

70 - 90 % son unilaterales
(el flujo proviene de la contralateral o de la A Infraorbitaria
1,7 % casos)

ALS ramos nasales
Septales y columelares

PubMed.gov

> Clin Anat. 2020 Mar;33(2):158-164. doi: 10.1002/ca.23379. Epub 2019 Apr 15.

Positional relationship of superior and inferior labial artery by ultrasonography image analysis for safe lip augmentation procedures

Kyu-Lim Lee [1], Hyung-Jin Lee [1], Kwan-Hyun Youn [2], Hee-Jin Kim [1 3]

Affiliations + expand

PMID: 30912205 DOI: 10.1002/ca.23379

Abstract

The aim of this study was to use ultrasonography to determine the locations and distributions of the superior labial artery (SLA) and the inferior labial artery (ILA) relative to the vermilion border (VB). Sixty healthy Korean volunteers (35 males, 25 females; age, 21-36 years) were investigated using ultrasonography. The participants had not received any noninvasive treatment or surgical procedure in the facial regions during the previous 6 months. Based on the VB, the overall thicknesses of the upper and lower lips were 9.4 ± 0.4 mm (mean ± SD) and 10.9 ± 0.7 mm, respectively. In most cases, the labial arteries were located in the wet mucosal layer on both the upper (35-57%) and lower lips (28-55%), respectively. In the upper lip, the SLA was in the intramuscular layer in 20-45% of cases, making it the second most common type. At some of the measuring points, the SLA was observed more often in the intramuscular layer than in the wet mucosal layer. In the lower lip, the ILA was also located in the dry mucosa (5-27%). The dry-wet mucosal junction is unclear in the lip area, and the ILA was commonly observed at the dry-wet mucosal junction. The arterial depth was 5.3 ± 0.3 mm in the upper lip and 4.2 ± 0.4 mm in the lower lip. The SLA and ILA are evenly distributed over all parts of the oral mucosa. Injection procedures for lip augmentation should therefore use very superficial approaches. Clin. Anat. 33:158-164, 2020. © 2019 Wiley Periodicals, Inc.

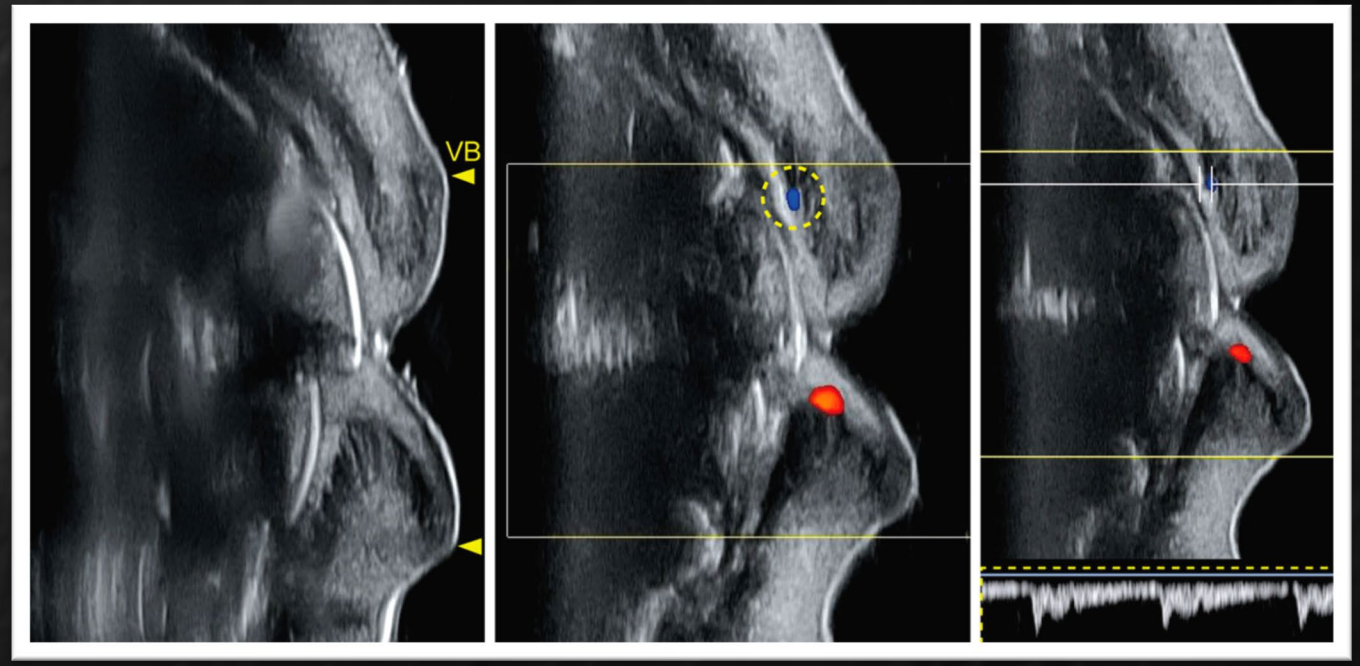

Posición de las arterias labiales

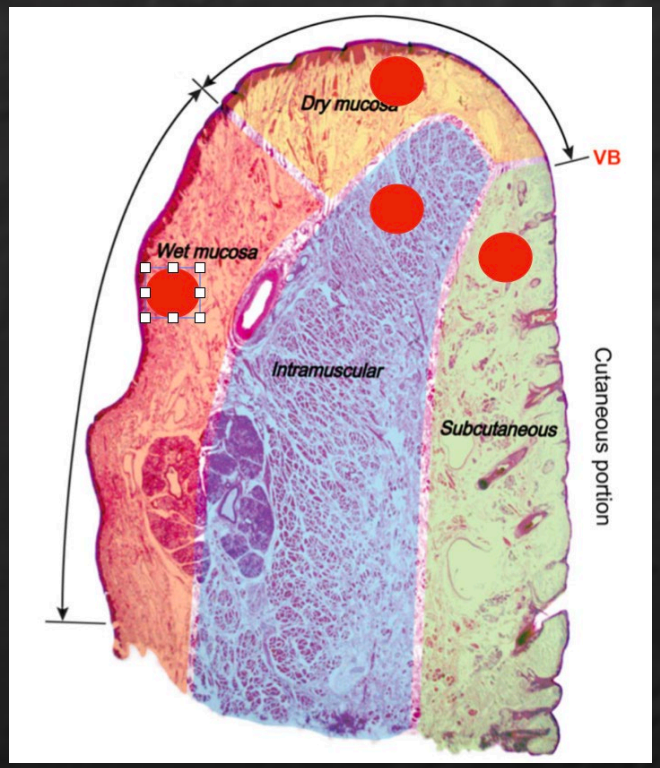

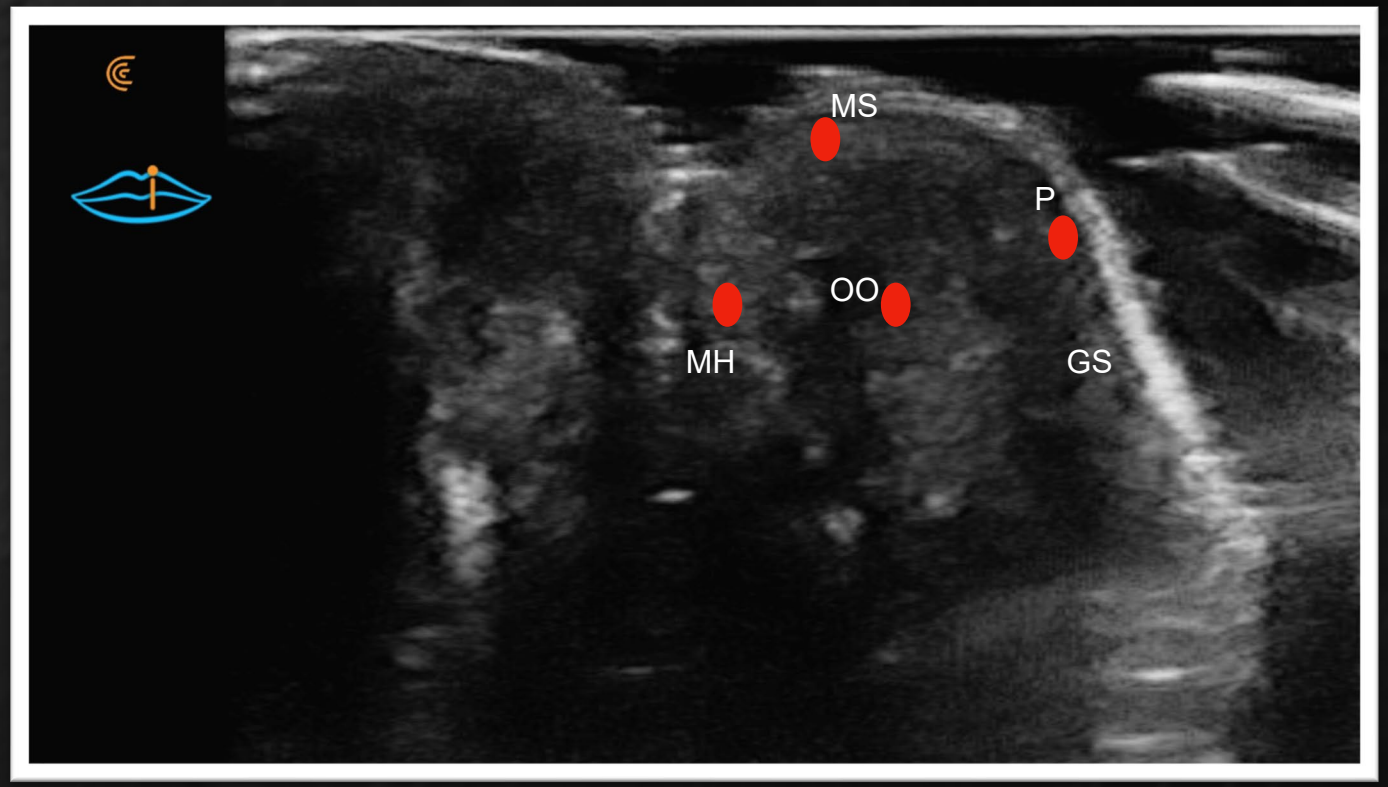

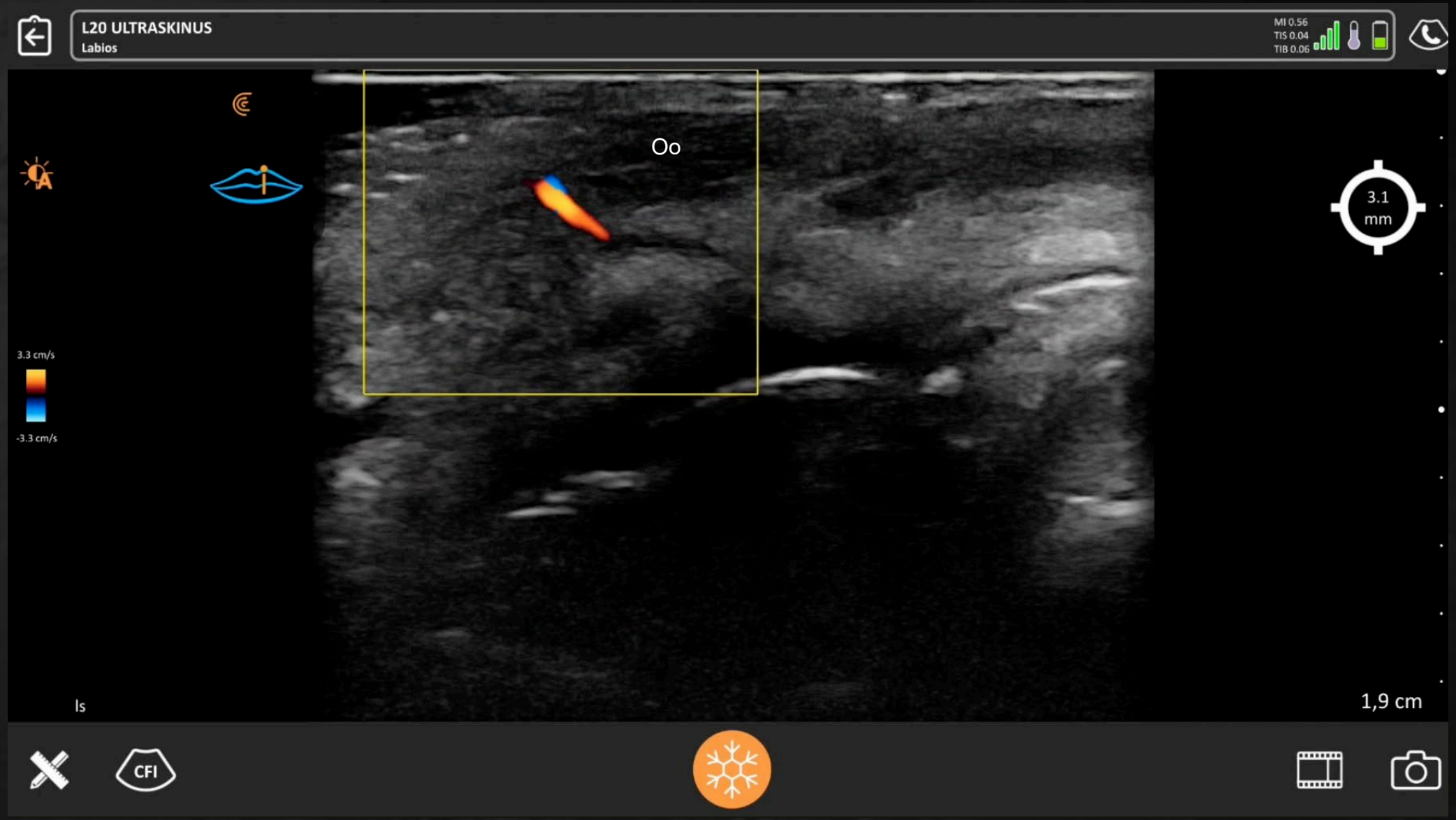
L20 ULTRASKINUS
Labios
MI 0.56
TIS 0.04
TIB 0.06
Oo
3.1
mm
3.3 cm/s
-3.3 cm/s
ls
1,9 cm
CFI

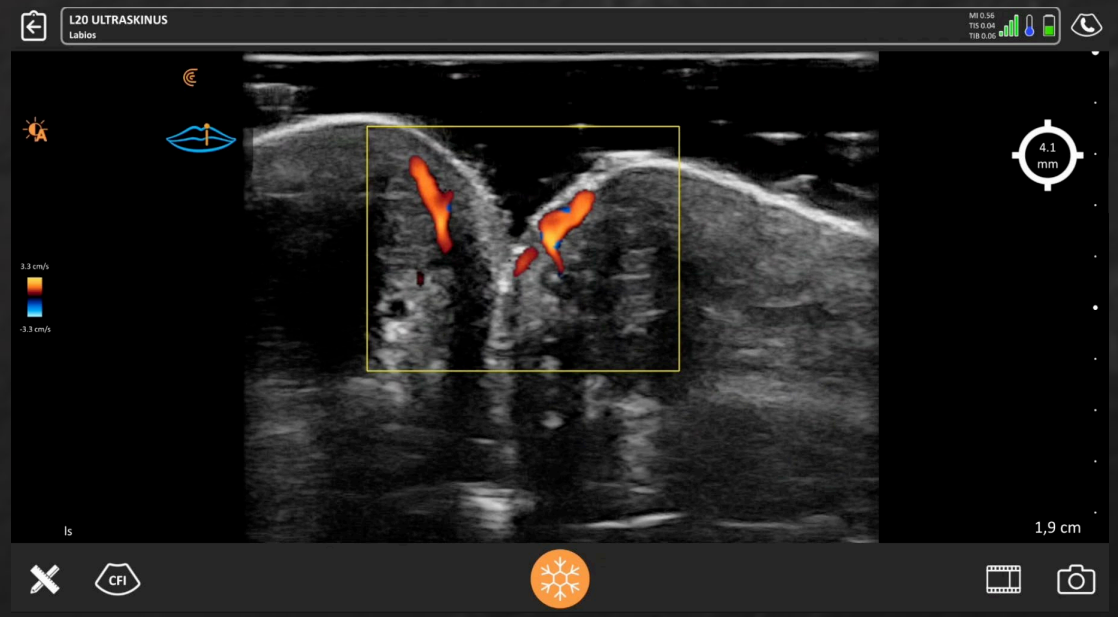
L20 ULTRASKINUS
Labios
MI 0.56
TIS 0.04
TIB 0.06
4.1 mm
3.3 cm/s
-3.3 cm/s
ls
1,9 cm
CFI

3.6 mm
00:23 / 00:29
1,9 cm

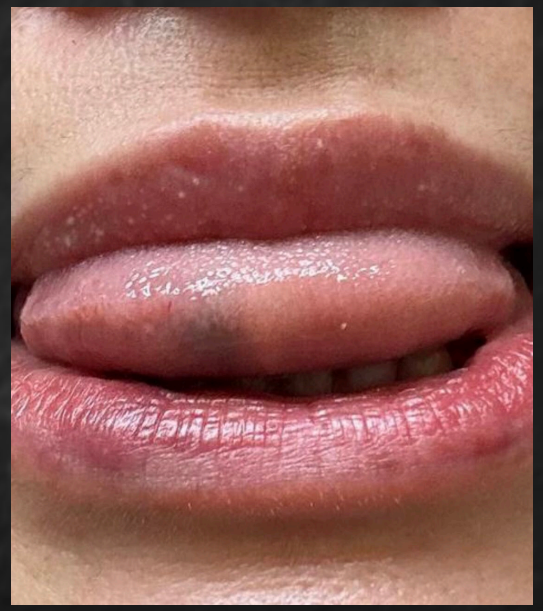


CRANIOFACIAL RESEARCH AND STUDY CENTER
MIAMI FLORIDA
Dr Patricia Oyole
Cirujana Maxilofacial

Eleni's L20
Aesthetics
D 25
4.792 mm
D 23
D 24
D 25
21 FPS / 16.0 MHz
1.5 cm
B

Fosa temporal

Zona de alto riesgo por su vascularización

Vasos Temporales SUPERFICIALES MEDIOS y PROFUNDOS todos ubicados anatómicamente en un área de poco espesor de tejidos blandos y poco extensible

Oclusiones vasculares :

diversos espectros

desde isquemias de tejidos blandos de diversos grados hasta ceguera

Ceguera : puede estar causada por al menos dos o mas vias factibles

Debemos evitar accidentes vasculares (embolias y obstrucciones por compresión externa)

Debido a la alta variabilidad de la disposición anatómica de los vasos , la técnica ideal es mediante el mapeo vascular y guía ecografica

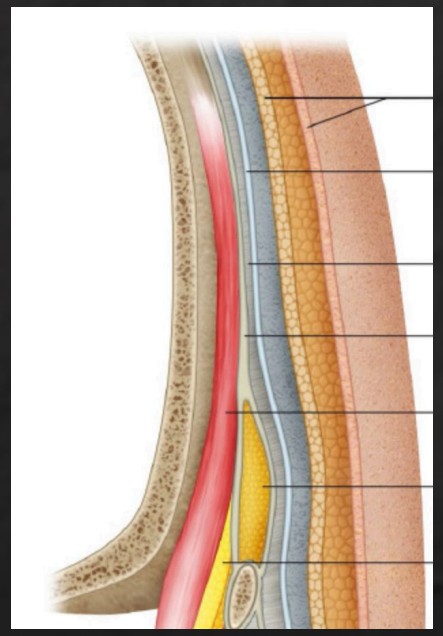

Plastic Surgery Key
Fastest Plastic Surgery & Dermatology Insight Engine

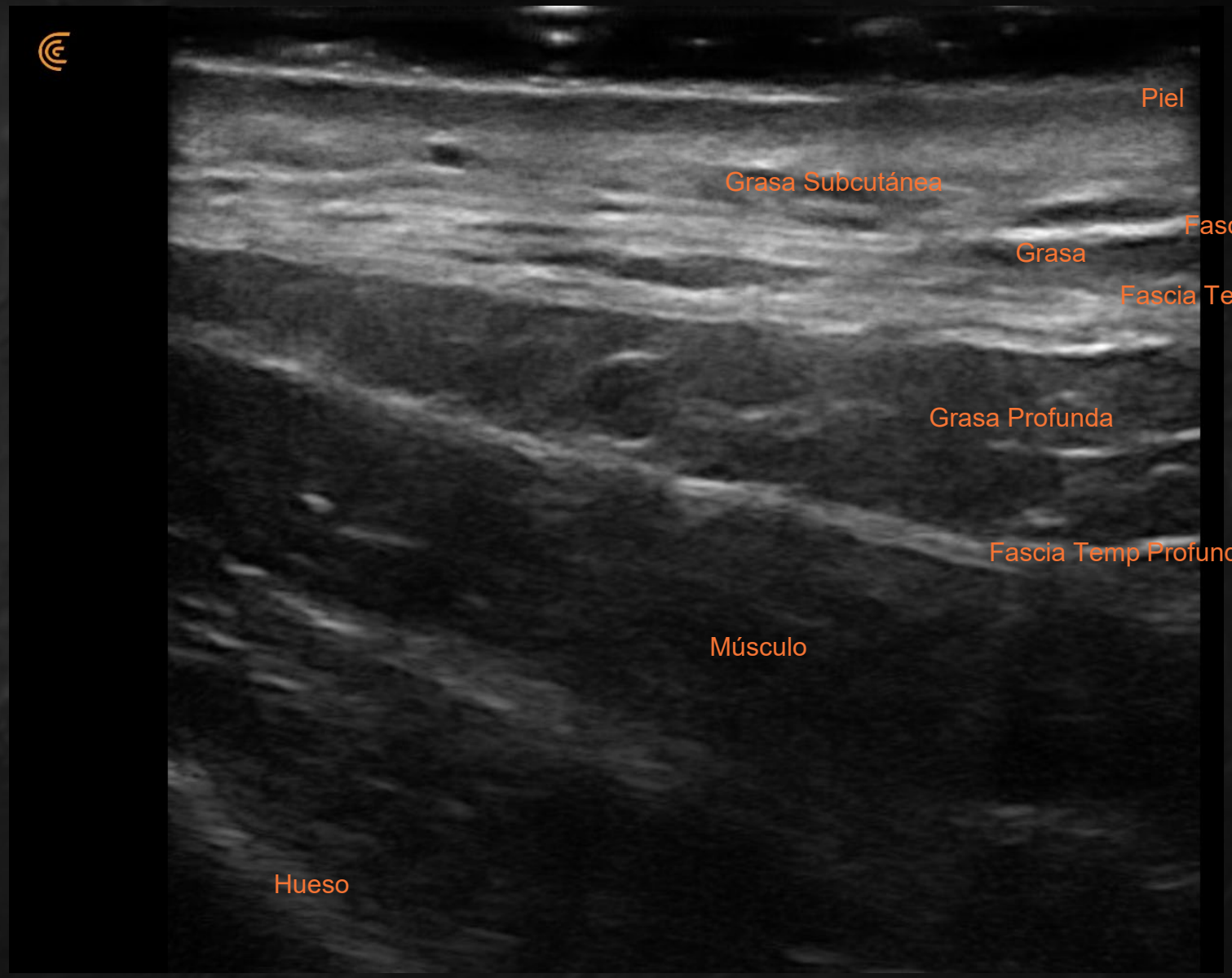

Técnica subcutánea :

Plano de implantación : grasa subcutánea

Riesgo: 1- Compresión Vena Centinela - 2- Lesión ATS rFrontal - ceguera

Técnica interfascial :

Plano de implantación : fascia sup- fascia profunda capa superficial

Riesgo: Lesión Vena temporal media

Técnica supraperióstica:

Plano de implantación : supraperiostio

Riesgo: Lesión Arteria Temporal Profunda r anterior ceguera

Arteria Temporal Superficial rama Frontal

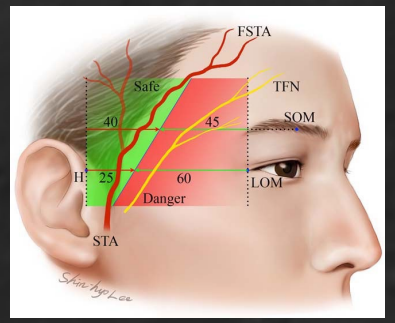

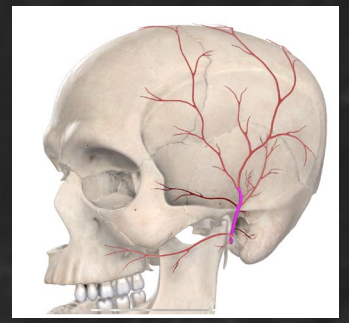

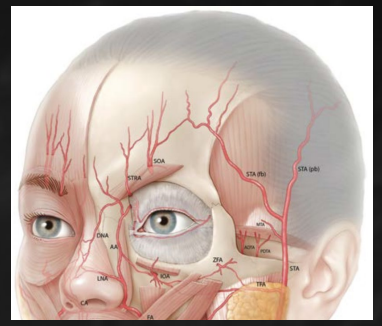

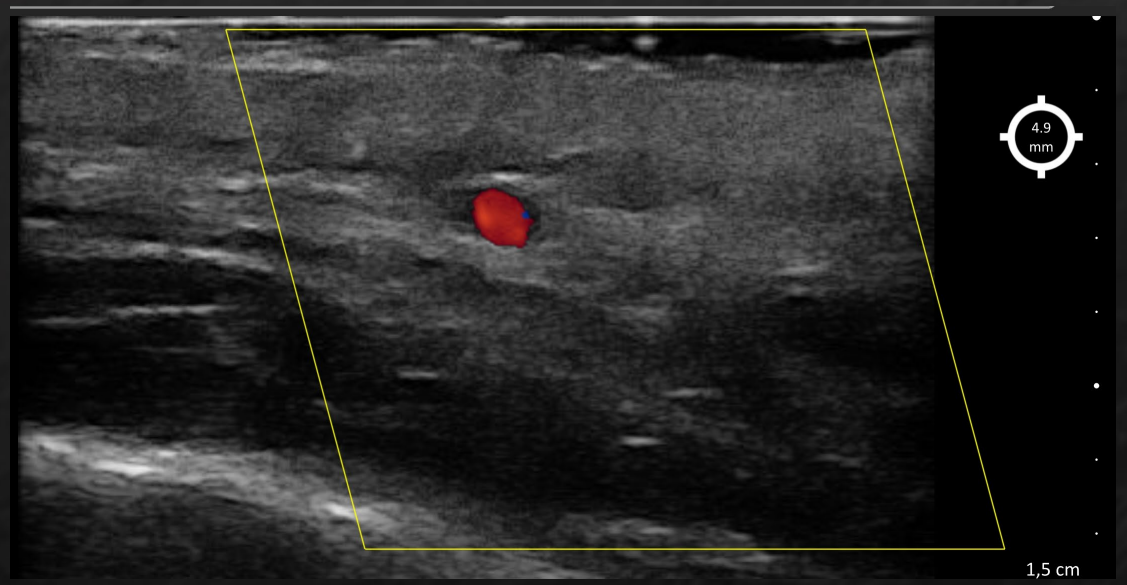

Anastomosis
ACE-ACI

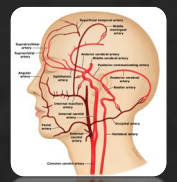

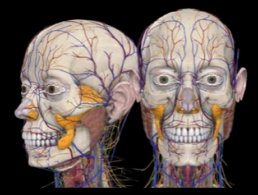

CRANIOFACIAL RESEARCH AND STUDY CENTER

MIAMI FLORIDA

Dr Patricia Oyole
Cirujana Maxilofacial

USA

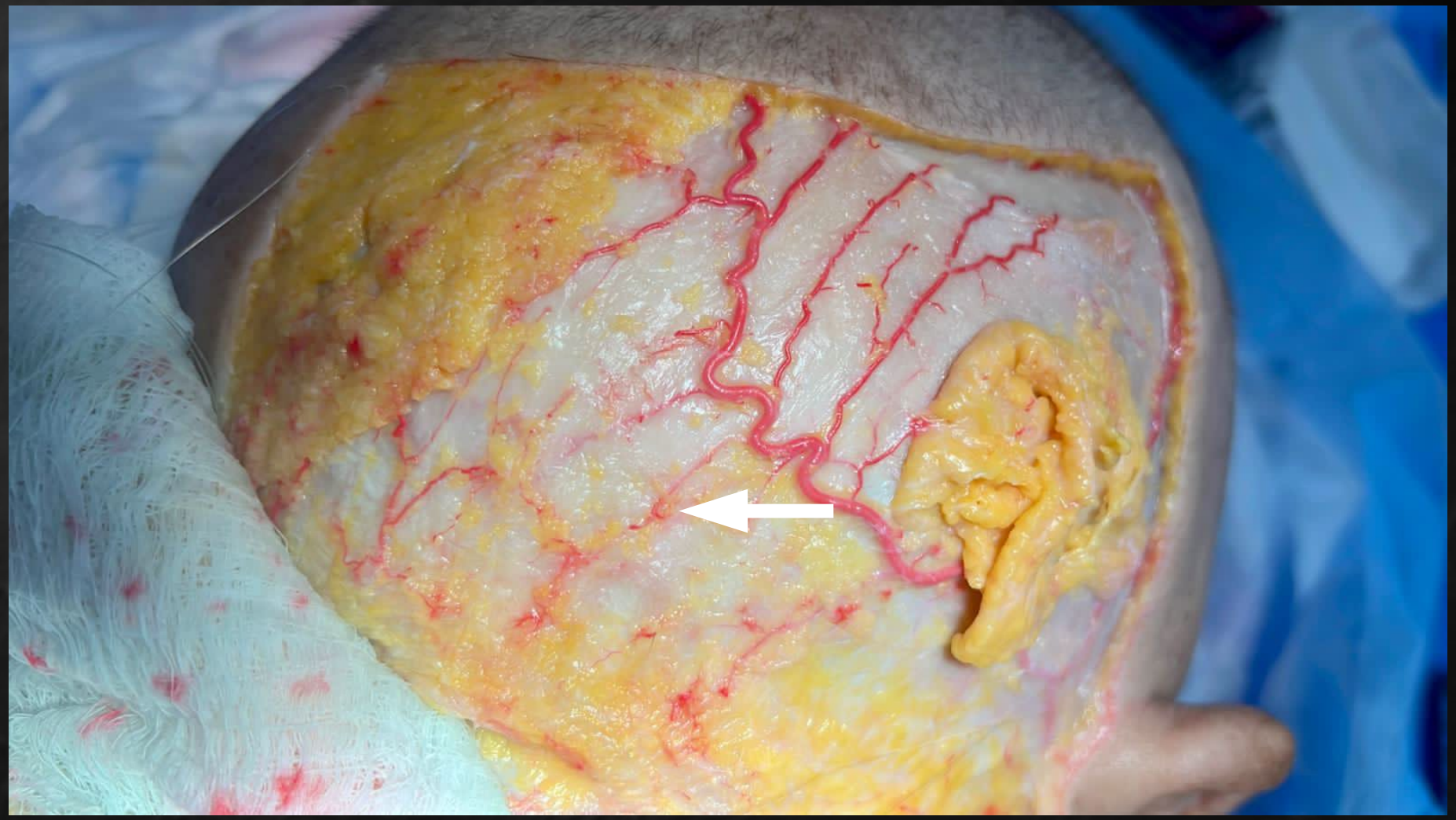

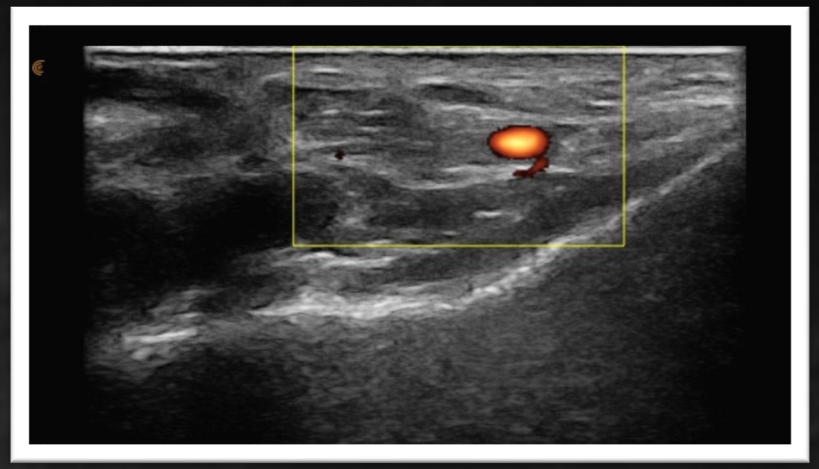


CRANIOFACIAL RESEARCH AND STUDY CENTER
MIAMI FLORIDA
Dr Patricia Oyole
Cirujana Maxilofacial
USA

Ténica Interfascial

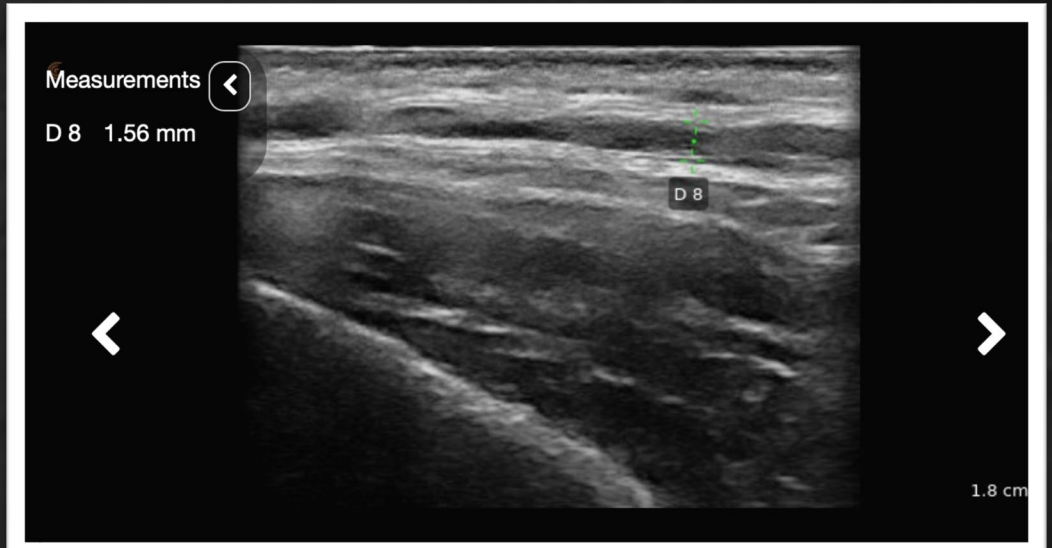

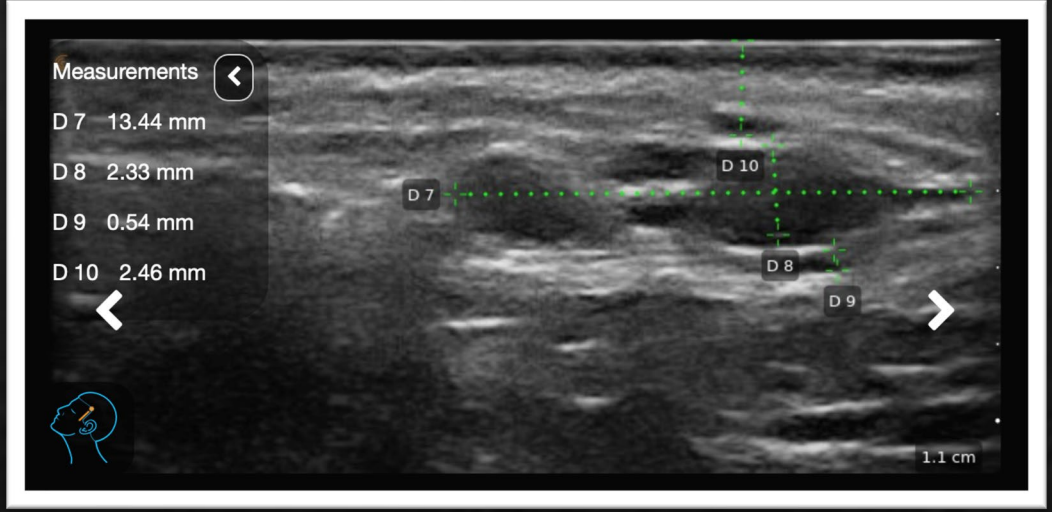

Vena Temporal Media

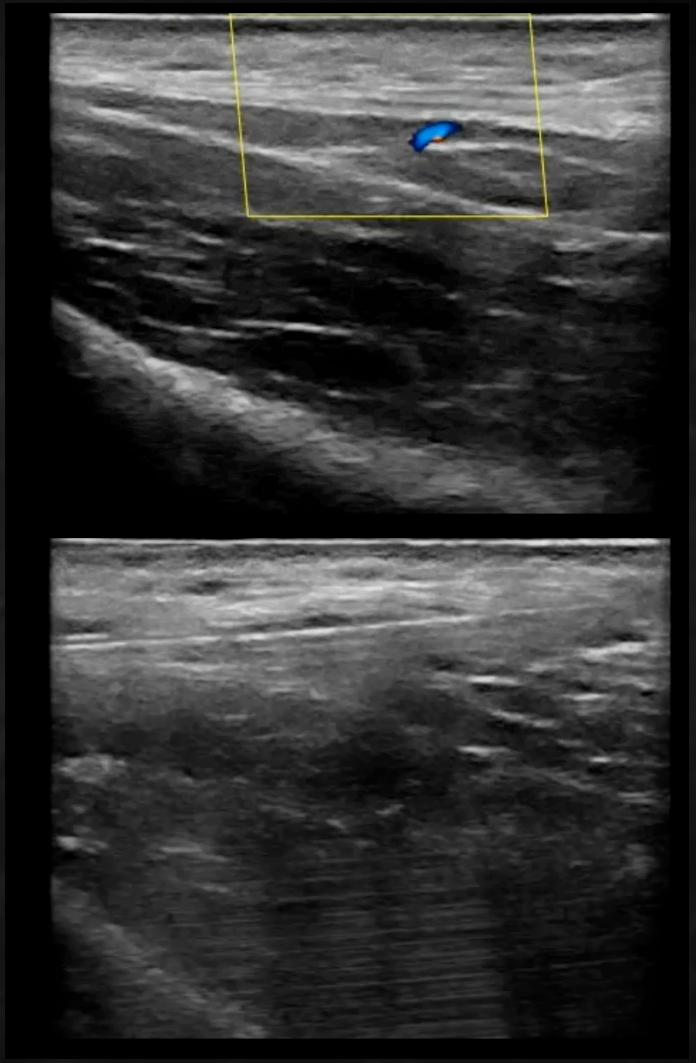

Arteria Temporal Profunda rama anterior

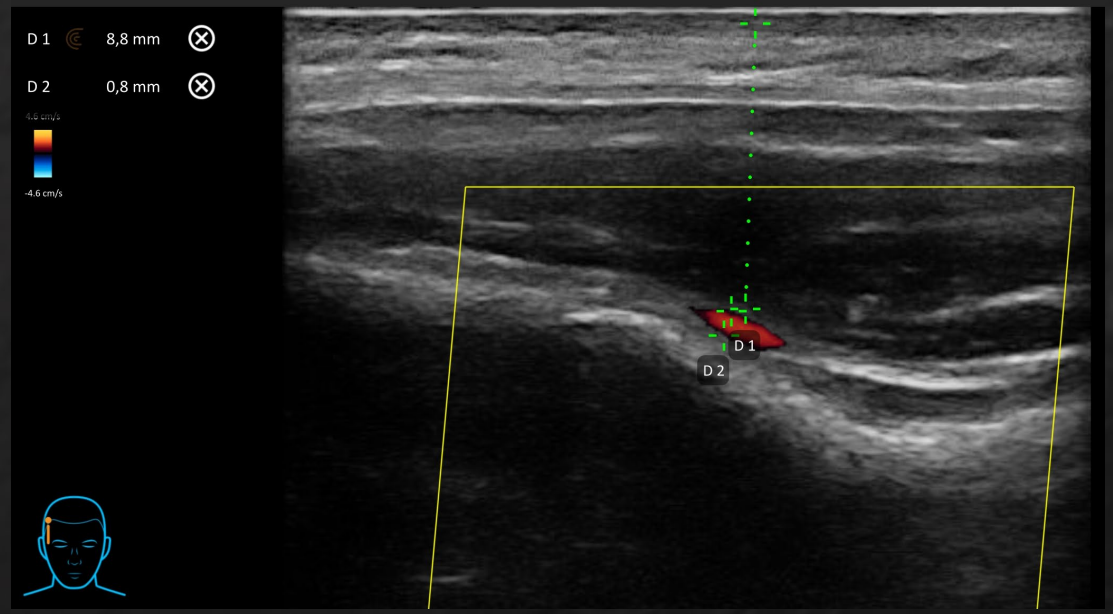

Arterias Temporales profundas 2-3-o 1 solo vaso irrigan al músculo

Técnica supraperióstica

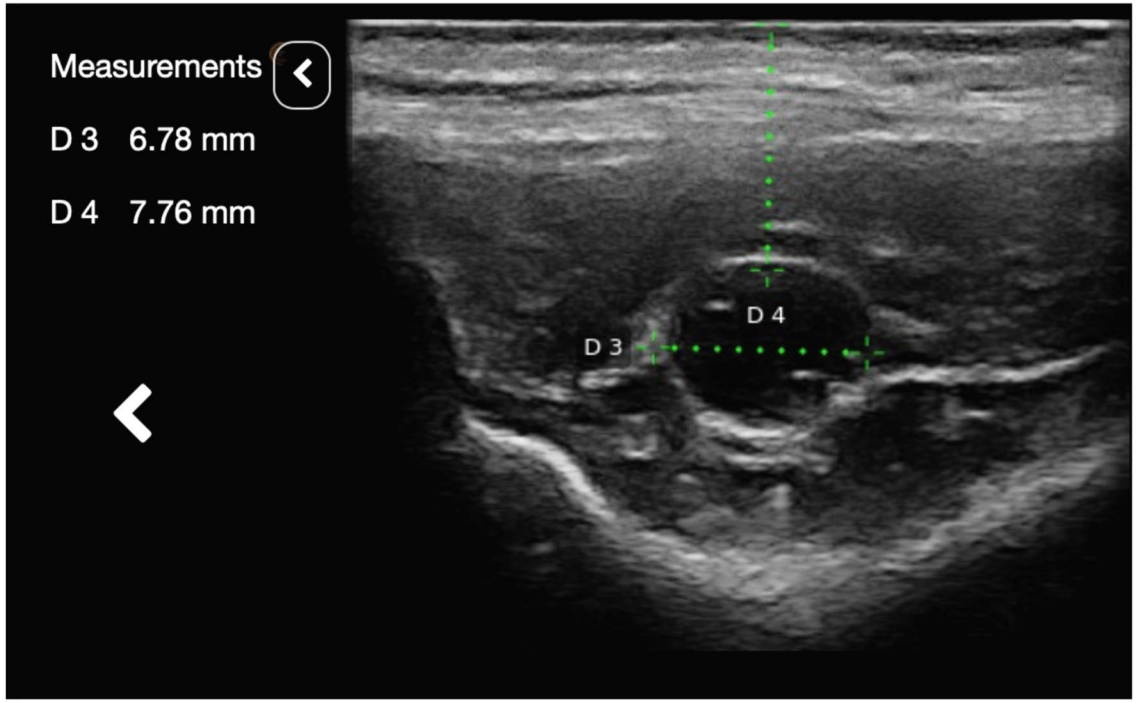

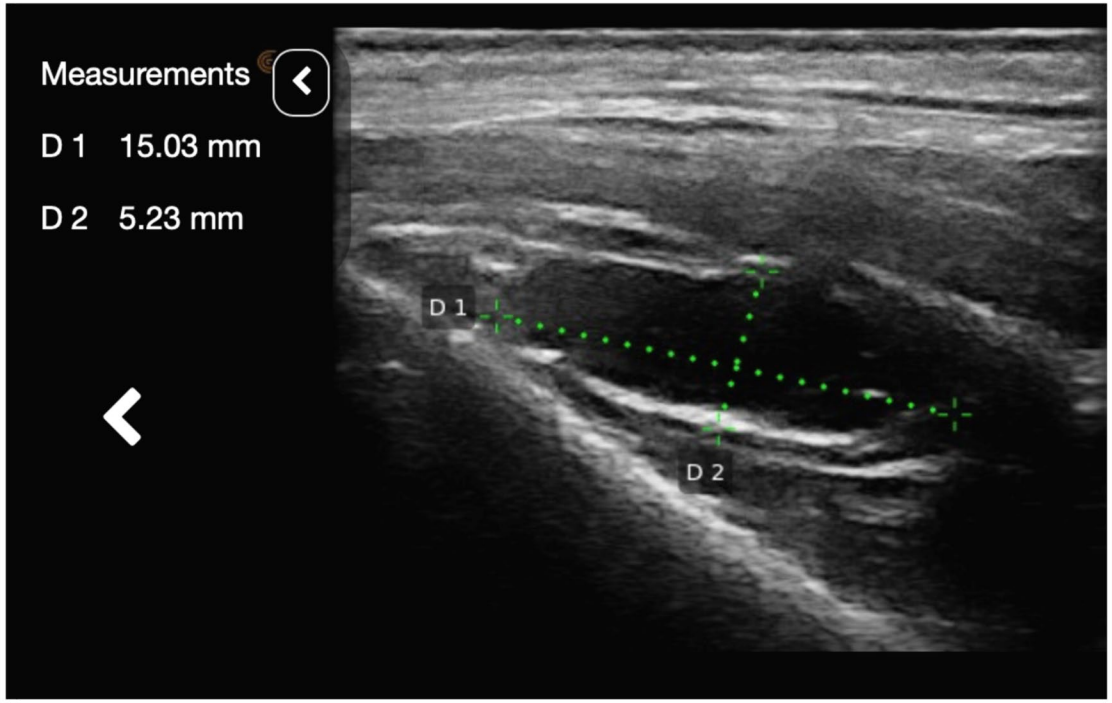

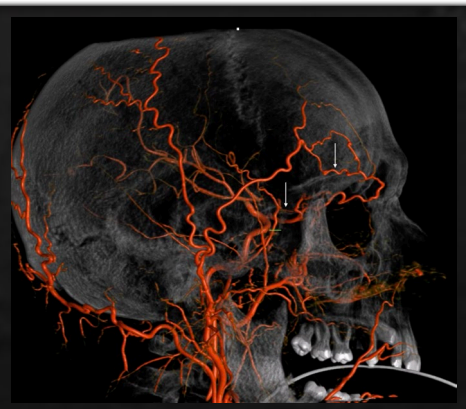

Riesgo : Isquemia tisular -ceguera -stroke
Anastomosis ATProf- art oftálmica (ramos lacrimales) y arteria cigomáticotemporal

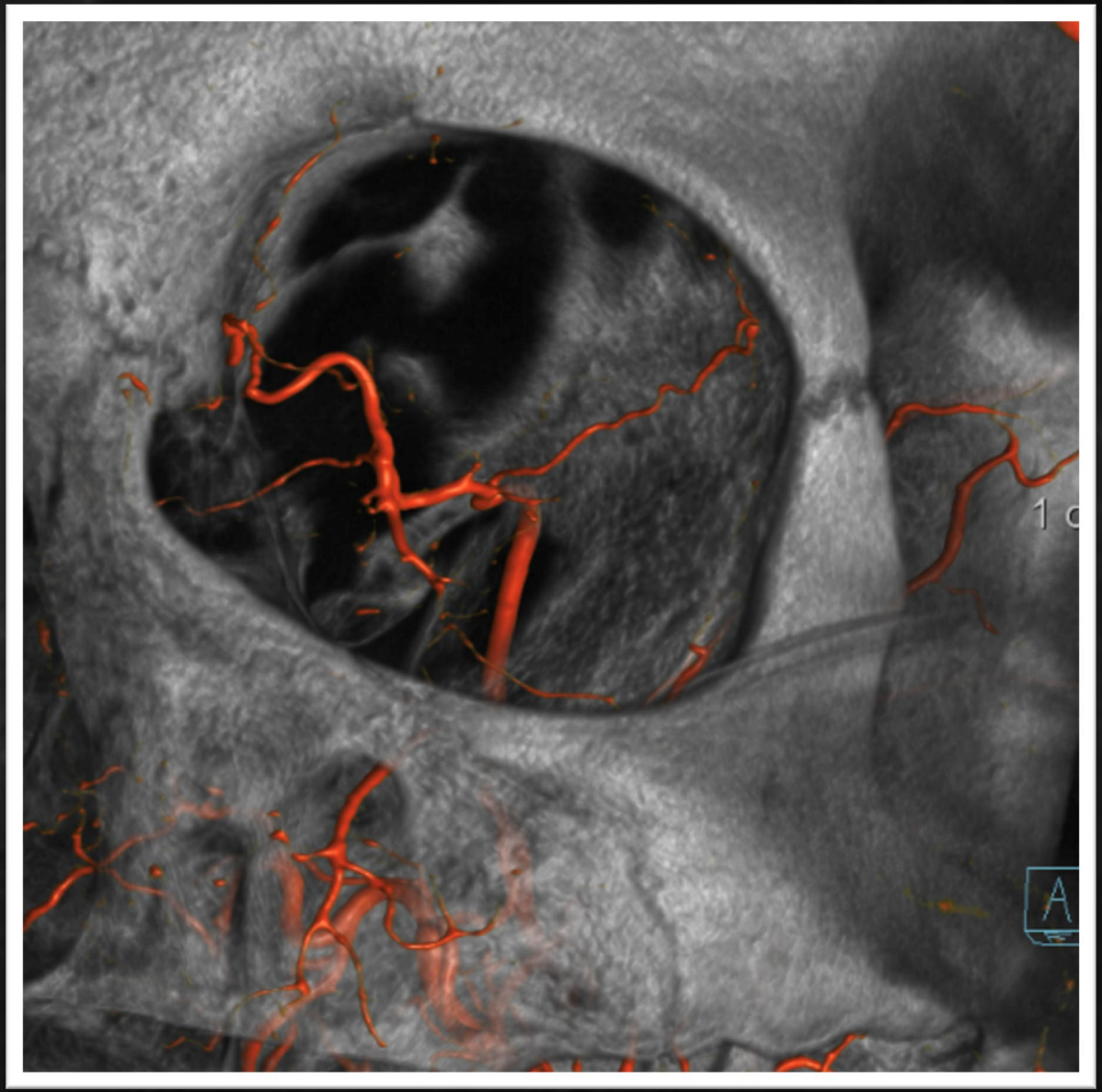

Anastomosis
ACE-ACI

Art ZT-AOf

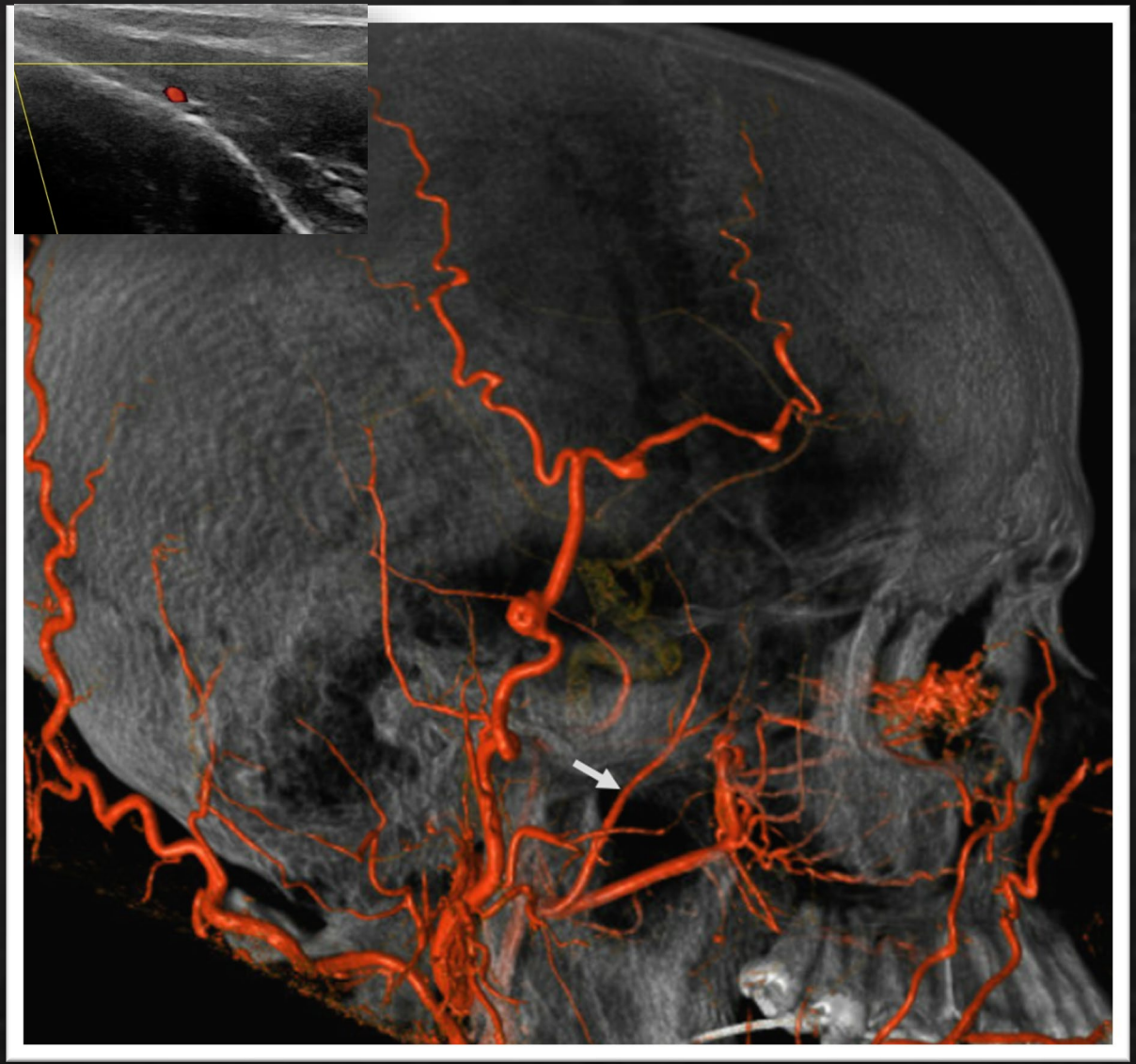

1 sola rama deep temporal

Deep temporal 2 ramas ant y posterior

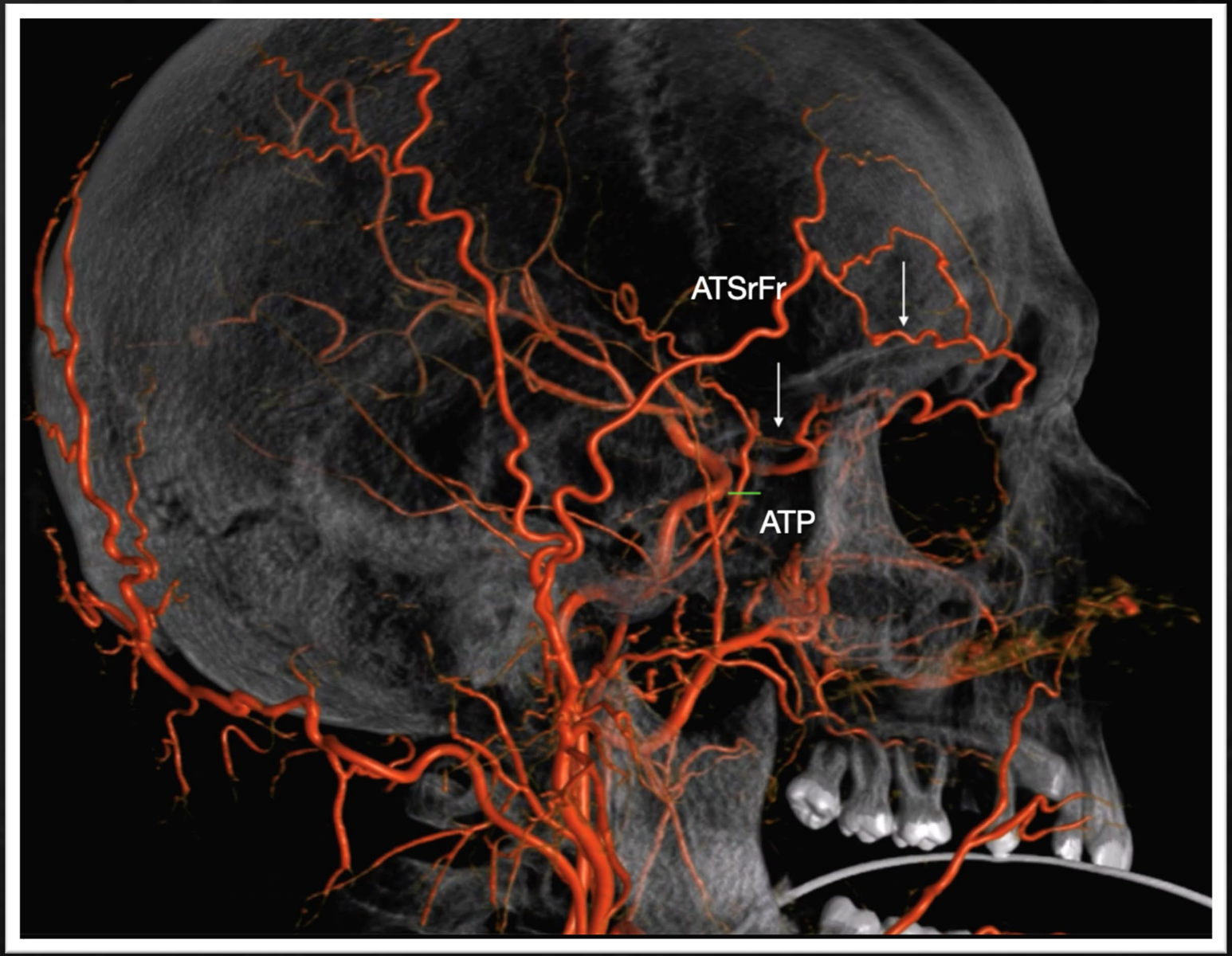
ATSrFr
ATP

Pómulos

<u>3 estructuras vasculares de riesgo:</u>

-Arteria Transversa facial

-Arteria Infraorbitaria

-Arteria Angular

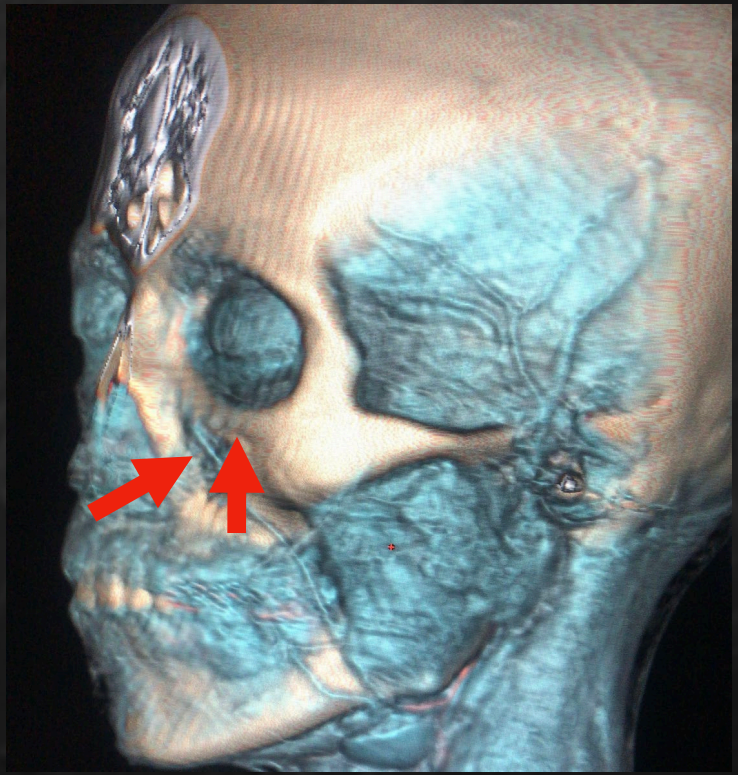

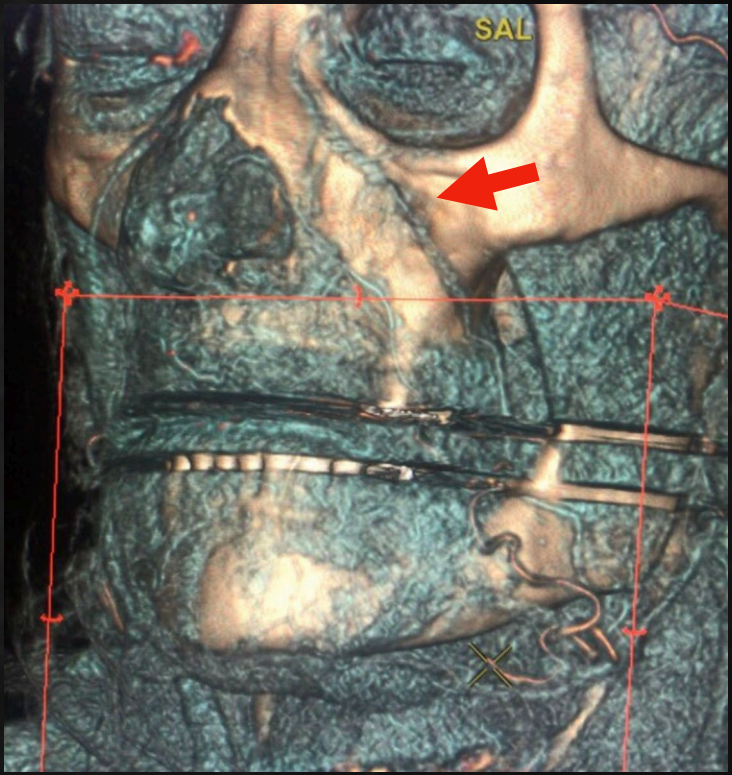

Arteria Transversa facial o Cigomático facial

PLoS One. 2019; 14(2): e0211974. PMCID: PMC6366864
Published online 2019 Feb 7. doi: 10.1371/journal.pone.0211974 PMID: 30730953

The transverse facial artery anatomy: Implications for plastic surgery procedures

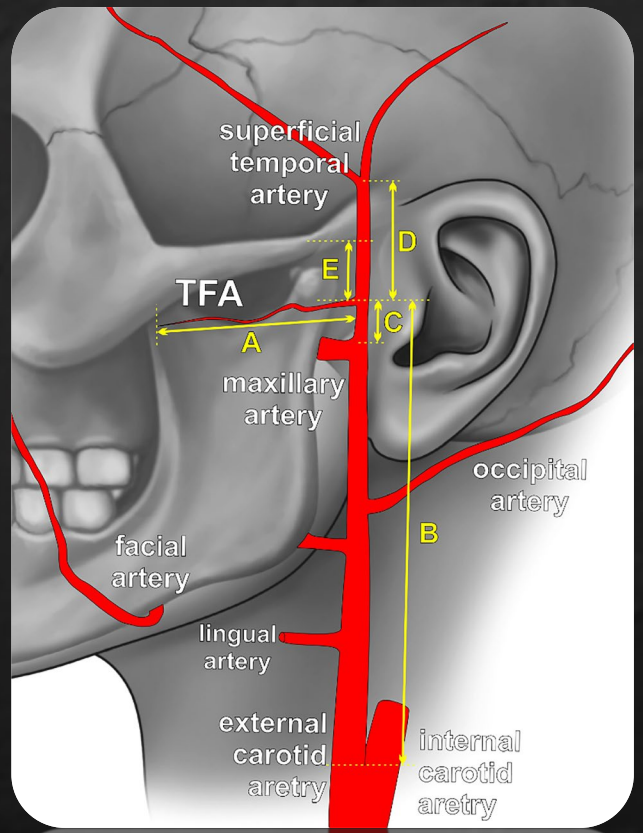

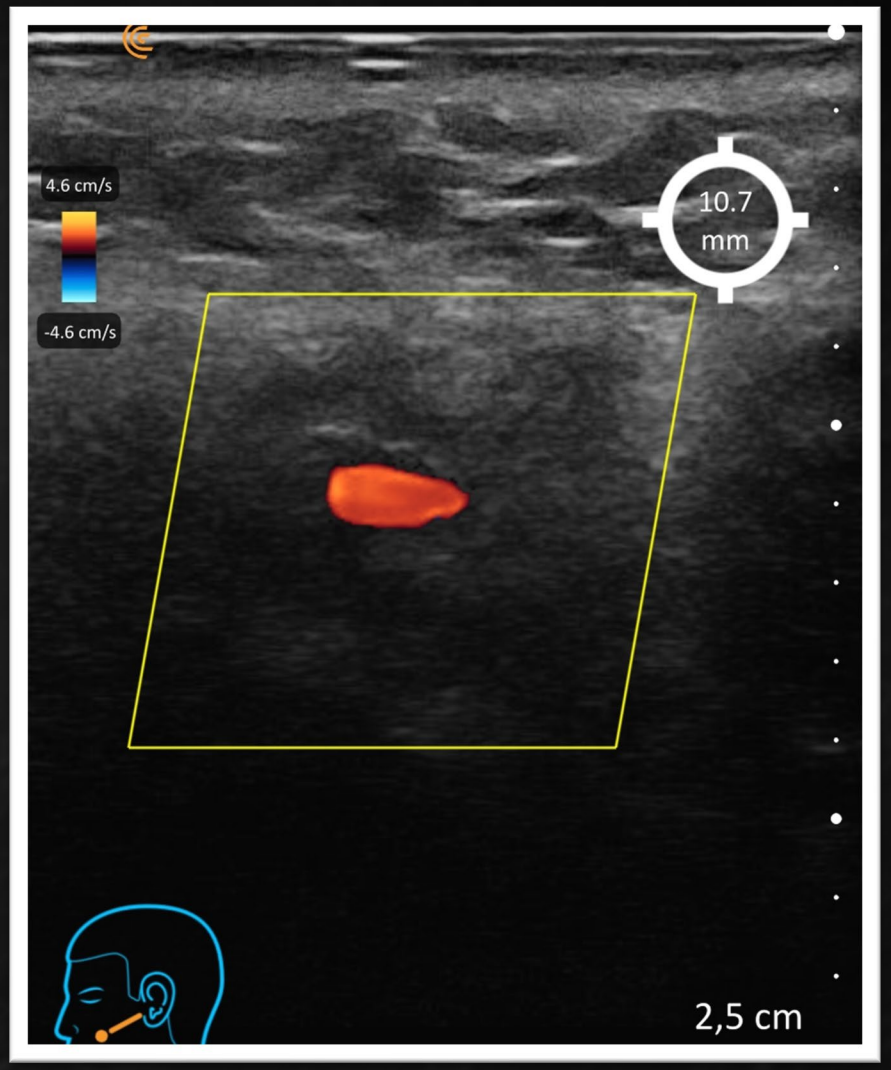

Arteria Infraorbitaria

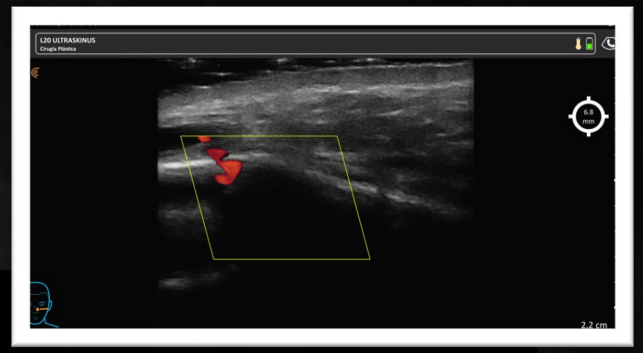

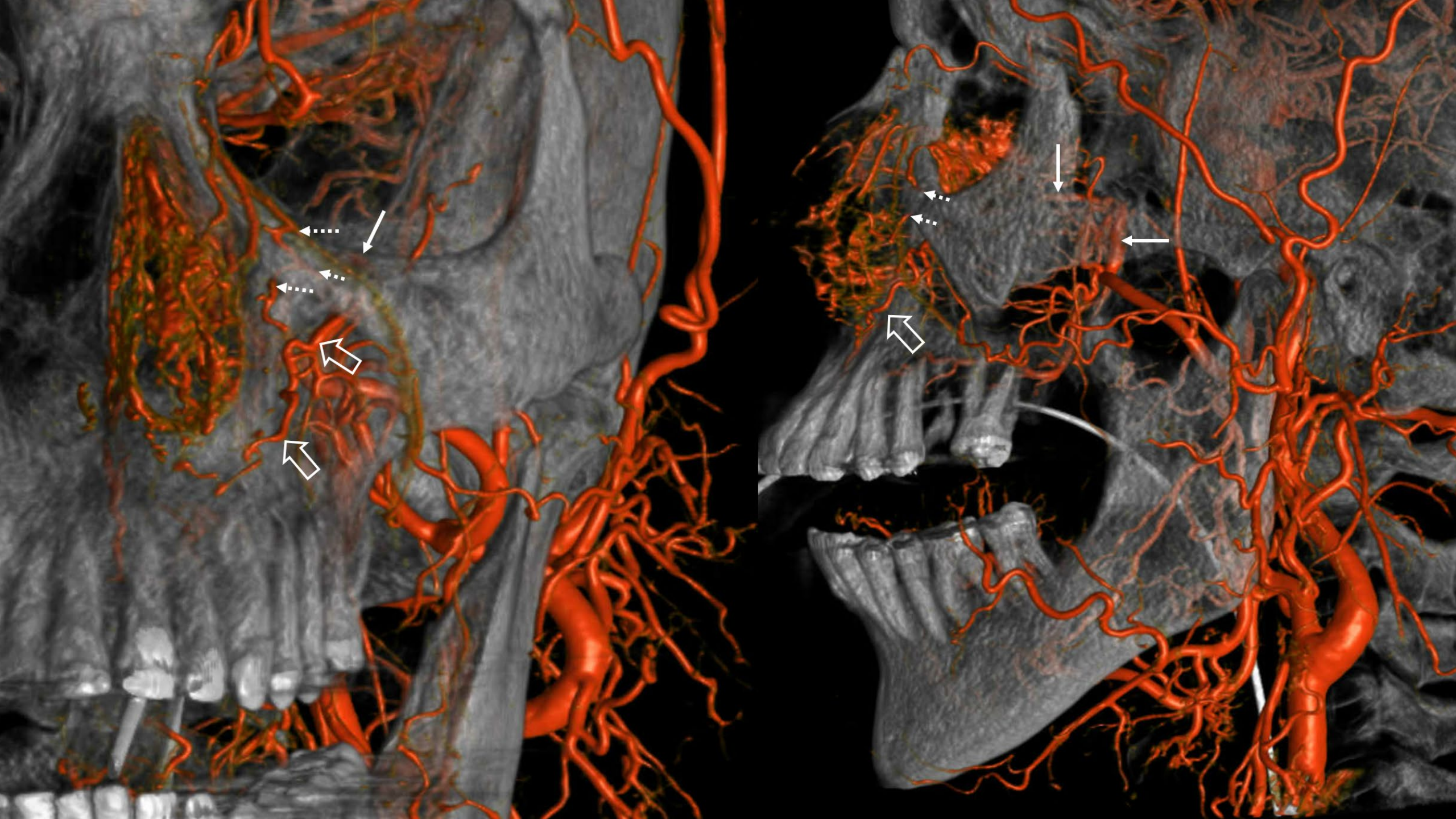

Conclusiones

Ecografia Doppler :

-Visualización vascular en tiempo real de los principales vasos maxilofaciales

La variabilidad vascular es muy alta e impredecible :

-Trayectoria (patrones de distribución y ramificación)
-Profundidad de los vasos
-Anastomosis ACE-ACI (1 a 5 sup y prof)
-Asimetría (D-I diferentes)

Mapeo vascular e intervenciones ecoguiadas son de fundamental importancia en los procedimientos estéticos

Us nos permite evitar accidentes vasculares iatrogénicos (isquemia tisular-ceguera-stroke)

Tratar accidentes vasculares

Inyección de Hialuronidasa ecoguiada

Follow up - espasmos vasculares (IR)

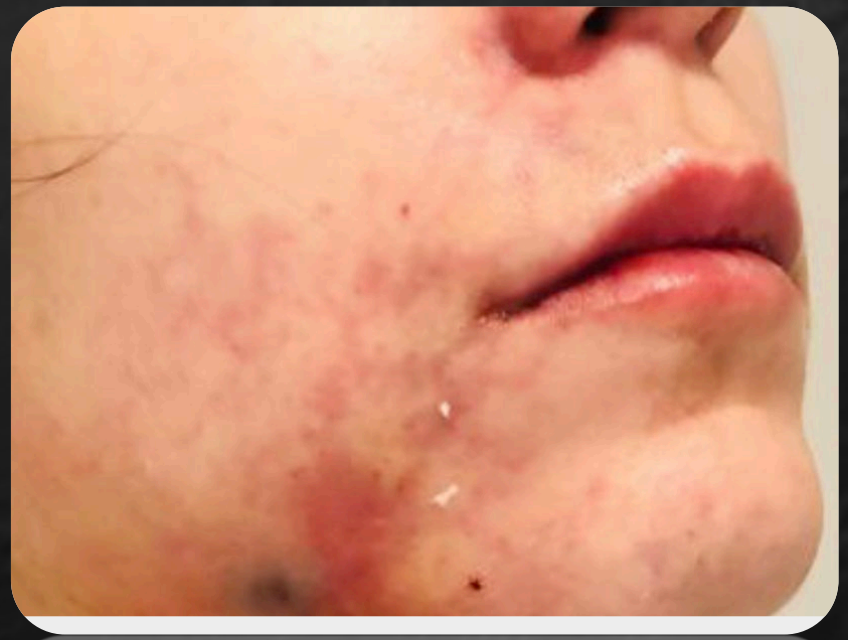

Pathophysiology, Clinical Manifestations, and Prevention of Ischemia-Reperfusion Injury FREE

Charles D. Collard, M.D.; Simon Gelman, M.D., Ph.D.

— Author and Article Information

Received from the Department of Anesthesiology, Perioperative and Pain Medicine, Brigham and Women's Hospital, Harvard Medical School, Boston, Massachusetts.

Anesthesiology June 2001, Vol. 94, 1133–1138.

https://doi.org/10.1097/00000542-200106000-00030

ischemia–reperfusion (I-R) injury

Muchas gracias

cursosdraravera@gmail.com

UltraSkinUS

ULTRASOUND BASIC & ADVANCED TRAINING

Demostración en directo

Rudy Meijer

Especialista Clínico

Europa |Medio Oriente | África

clarius Ultrasound Anywhere

Encuesta

¿Qué le gustaría saber?

- *Obtener precio / cotización*
- *Hablar con uno de nuestros expertos sobre las ventajas del ultrasonido inalámbrico*
- *Hablar de las características del escáner*
- *Agendar una demostración*
- *Ver más tutoriales*

Clarius L20 HD3

30% Màs pequeño & Màs asequible

Inalàmbrico

Imagen de alta definición

Aplicación fácil para su iOS o Android

Paquete de Estética Advanzada

Almacenamiento en la nube Clarius

Clarius Live Telemedicina

Usuarios ilimitados

Preguntas?

Dra. Karina Ravera

Rudy Meijer

clarius

clarius

¡Gracias!